

## Effects of Focused Ultrasound Sonodynamic Treatment on the Rat Blood–Brain Barrier

SHIN-ICHIRO YOSHINO<sup>1</sup>, TAKEO FUKUSHIMA<sup>1</sup>, SHUJI HAYASHI<sup>1</sup>, MASANI NONAKA<sup>1</sup>,  
KOHICHI OGAWA<sup>2</sup>, KAZUNARI SASAKI<sup>3</sup> and SHIN-ICHIRO UMEMURA<sup>3</sup>

Departments of <sup>1</sup>Neurosurgery and <sup>2</sup>Anatomy, Fukuoka University Faculty of Medicine, Fukuoka;  
<sup>3</sup>Advanced Research Laboratory, Hitachi, Ltd., Saitama, Japan

**Abstract.** *Background:* Ultrasound has recently been applied to the treatment as well as the diagnosis of various pathologies, and its antitumor effects in the treatment of human cancer and experimental models of cancer have been demonstrated. In addition, it is possible that certain photosensitizers will enhance the antitumor effects of ultrasound. However, very few studies have been reported on how the blood–brain barrier is affected by sonodynamic therapy. The purpose of this study was to evaluate disruption of the blood–brain barrier with focused ultrasound with a photosensitizer, for clinical application of sonodynamic therapy to brain tumors. *Materials and Methods:* Rat brains were subjected to focused ultrasound irradiation via a transducer with or without prior intravenous injection of photosensitizer, and lesions were examined histologically by electron microscopy. *Results:* Electron microscopically, swelling of astroglial processes, denatured cells, protoplasm of endothelial cells, and mitochondria were observed in the center and border of regions of ultrasonic irradiation. There were numerous pinocytotic vesicles in the cytoplasm of the endothelial cells. In addition, disruption of the cytoplasmic membrane of endothelial cells and astroglia was found in these regions. *Conclusion:* These findings suggest that sonodynamic therapy with a photosensitizer affects the blood–brain barrier, and that blood vessel permeability increases not only as a result of destruction of the blood–brain barrier but also by disruption of the cytoplasmic membrane of endothelial cells.

Malignant glioma is characterized by strong local invasiveness and rapid growth, making it difficult to obtain complete cure with surgical treatment. Radiochemoimmunotherapy is thus

required after tumor extraction. Even with these treatment modalities, it is difficult to control local recurrence, and average survival rates are 50.5% and 7.6% at one year and five years, respectively (1-3). Recently, antitumor effects of ultrasound have been demonstrated and it has come to be considered a new treatment modality for aggressive, locally invasive lesions. Focused ultrasound with a photosensitizer could enhance the antitumor effects of ultrasound and thus function as a new treatment modality for locally invasive malignant tumors (4-12, 28).

The mechanisms by which ultrasound exhibits antitumor effects include: i) mechanical effects, such as destruction and perforation due to mechanical vibration, as well as cavitation-induced heating and superoxide production; ii) chemical effects such as drug activation and promotion of reactions, which was applied to thrombolytic therapy by urokinase, and iii) effects of heating, as in thermotherapy of cancer or physiotherapy for arthralgia (13, 29). Photosensitizers which enhance ultrasound include anthracycline antibiotics such as daunomycin and doxorubicin, as well as hematoporphyrin derivatives such as xanthene dyes (*e.g.* Rose Bengal).

Previously, we performed a basic study on the effects on brain tissue of sonodynamic therapy. Focused ultrasound was applied between 25 and 150 W/cm<sup>2</sup> intensity at 1.04 MHz over 5 to 10 minutes, with Rose Bengal administered as a photosensitizer at 10 or 50 mg/kg. Exposure at 25 W/cm<sup>2</sup> at 1 Mhz for 5 minutes was safe for normal rat brain, while a peak focus intensity of 100 W/cm<sup>2</sup> at 1 Mhz with more than 3 minutes of exposure with or without Rose Bengal produced lesions of coagulation necrosis in rat brain. We performed sonodynamic therapy for transplanted tumor in rat brain using focused ultrasound with Rose Bengal. In these experiments, we confirmed that sonodynamic therapy was effective in treatment of experimental rat glioma *in vivo* and also for human malignant glioma cells *in vitro*, and that antitumor activity was enhanced by combination with a photosensitizer (14).

In these experiments, it was thus proven that sonodynamic therapy exhibited significant antitumor effects,

*Correspondence to:* Shin-ichiro Yoshino, MD, Department of Neurosurgery, Fukuoka City Hospital, 13-1 Yoshizukahonmachi, Hakata-ku, Fukuoka 812-0046, Japan. Tel: +81 926321111, Fax: +81 926320900, e-mail: yoshino.s02@city.fukuoka.jp

*Key Words:* Sonodynamic therapy, photosensitizer, normal rat brain, blood–brain barrier, electron microscopic study.

although the mechanism by which it did so remained unclear. In the present study, we therefore used electron microscopy to examine the effects on the blood-brain barrier (BBB) in rat brain irradiated by focused ultrasound with a photosensitizer.

## Materials and Methods

Adult female Wistar rats (weight 250-300 g; Seack Yoshitomi, Japan) were used in this study.

*Preparation of focused ultrasound device.* A focused ultrasound transducer was used ( $\phi$ 10 mm; Hitachi, Ltd.). It is provided with piping for cooling to prevent overheating inside of the transducer, and the temperature was kept at 25°C during sonication. The overall resonant frequency of the transducer was 1.04 Mhz, and sinusoidal activity was generated by a wave generator (Model MG442A; Anritsu Electric, Japan) where output was amplified by an RF amplifier (model 210L; ENI, USA). The signal of the transducer was monitored by an oscilloscope during ultrasound exposure. The target depth of the ultrasound was 4 mm in depth from the transducer rim, with the ultrasound directed 2 to 3 mm axially and 1 to 2 mm laterally.

*Method of ultrasound irradiation.* Rats were anesthetized intraperitoneally with sodium pentobarbital (40 mg/kg), and the head was fixed in a stereotactic device after sterilization with alcohol. A 2-cm midline skin incision was performed in the parietal region, and a 10-mm diameter craniotomy was carried out using a high-speed dental drill after dissecting the pericranial tissue. The transducer was applied to the dural surface while gelatin-coated. The brain was sonicated at 100 W/cm<sup>2</sup> intensity for 3 or 5 minutes, which produced destructive lesions.

*Preparation of a sonodynamically active agent (Rose Bengal).* Rose Bengal (disodium tetraiodo-tetrachloro-fluorescein; Wako Chemical Company, Tokyo, Japan), a xanthene dye, was diluted to 10 mg/ml with isotonic sodium chloride solution and filtered at 0.22  $\mu$ m. The brain was sonicated 5 minutes after intravenous administration of Rose Bengal at 10 mg/kg. In the control group, isotonic sodium chloride solution of the same amount was administered before sonication. The animals were killed one hour after sonication.

*Preparation of sonicated brain tissue.* A 2% Evans blue solution (2 mg/kg) was administered *via* the right femoral vein 15 minutes prior to sonication. The brain was perfused with 100 ml of heparin containing Ringer's solution and was fixed with 100 ml of a 2.5% glutaraldehyde solution (pH 7.2, 25% glutaraldehyde + distilled water + 0.1 M cacodylic acid sodium buffer solution). After the brain had been cut into 1 mm slices coronally and fixed with 2.5% glutaraldehyde solution, the lesion was cut at 1 mm thickness in the central and peripheral regions of sonication. Thereafter, the specimens were fixed with 2.5% glutaraldehyde solution for 2 hours and washed in 0.1% cacodylic acid sodium buffer solution. Specimens were then fixed with 1.0% osmium tetroxide (4.0% osmium acid liquid + 0.1M cacodylic acid sodium buffer solution) for 2 hours and then washed with distilled water, followed by alcohol dehydration, propylene oxide processing, and flat embedding in Epon-Araldite. Semi-ultra-thin sections stained with

toluidine blue were observed on a microscope to examine the lesion, and ultra-thin sections were then cut and stained with uranyl acetate and lead citrate, and examined on a transmission electron microscope (H-7100; Hitachi Ltd.)

## Results

A 100 W/cm<sup>2</sup> peak focus intensity was used with or without Rose Bengal, with 3-minute sonication.

We classified rats into three groups: one sonicated without Rose Bengal and the other with it, as well as a control group without sonication.

*Macroscopic findings.* In brain sonicated without Rose Bengal, a limited, narrow region of the brain was stained slightly with Evans blue, while in brain sonicated with Rose Bengal the region stained in Evans blue was wider and densely stained, with wider and prominent BBB disruption. These findings were compatible with those of our previous studies.

*Electron-microscopic findings. Non-sonicated group:* There were no abnormal capillary endothelial cells, processes of astroglia, or nuclei of neurons at low magnification (Figure 1a). At intermediate magnification, examination of capillaries (Figure 1b) revealed endothelial cells positioned on the basement membrane and a few pericytes were observed. Processes of astrocytes faced the basement membrane. On high-magnification examination of endothelial cells (Figure 1c), there were no abnormalities in the nuclei, cytoplasm, or tight junctions.

*Ultrasound without Rose Bengal group:* In the central zone of the lesion, astrocytic processes were swollen and some cytoplasm had degenerated. Cytoplasm of the endothelial cells was swollen, with swollen mitochondria and pinocytotic vesicles. However, there were no clear abnormalities of tight junctions of endothelial cells. In the peripheral zone, astrocytic processes were slightly swollen (Figure 2a) and endothelial cells were normal (Figure 2b).

*Ultrasound with Rose Bengal group:* In the central zone, astrocytic and neuronal processes were swollen, and degenerated cells were observed (Figure 3a). Capillaries were surrounded by swollen processes of astrocytes (Figure 3b). Endothelial cells were swollen, and numerous pinocytotic vesicles and swollen mitochondria were observed in the cytoplasm (Figure 3c). Disruption of the cytoplasmic membrane was observed in some endothelial cells (Figure 3d). On high magnification (Figure 3e), tight junctions of endothelial cells were few and no structural abnormalities were noted. In the peripheral zone, there were swollen astrocytic processes and disruption of cytoplasmic membrane, swollen cytoplasm and mitochondria, and increased presence of pinocytotic vesicles in endothelial cells.

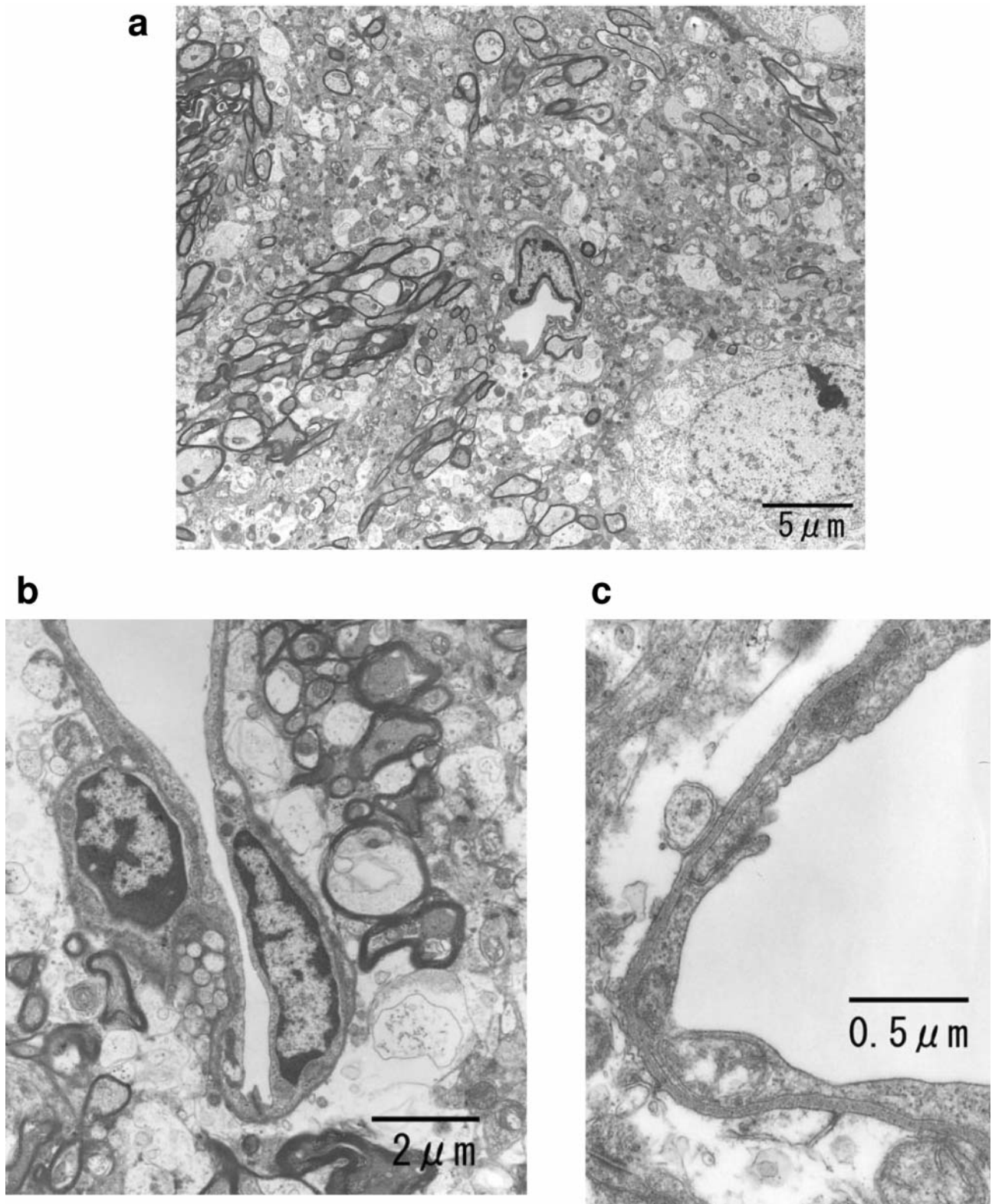


Figure 1. Electron-microscope images of normal unirradiated rat brain. a) V: Capillary, N: nucleus of a nerve cell,  $\times 4,400$ ; b) A capillary. Basement membrane (B) surrounding the outside of the endothelium (E). A process of an astrocyte (A) in contact with basement membrane. P: Pericyte,  $\times 13,000$ ; c) Magnified images of the endothelium. Endothelial cells (E) face tight junctions (arrow). A: Process of an astrocyte, B: Basement membrane,  $\times 54,000$ .



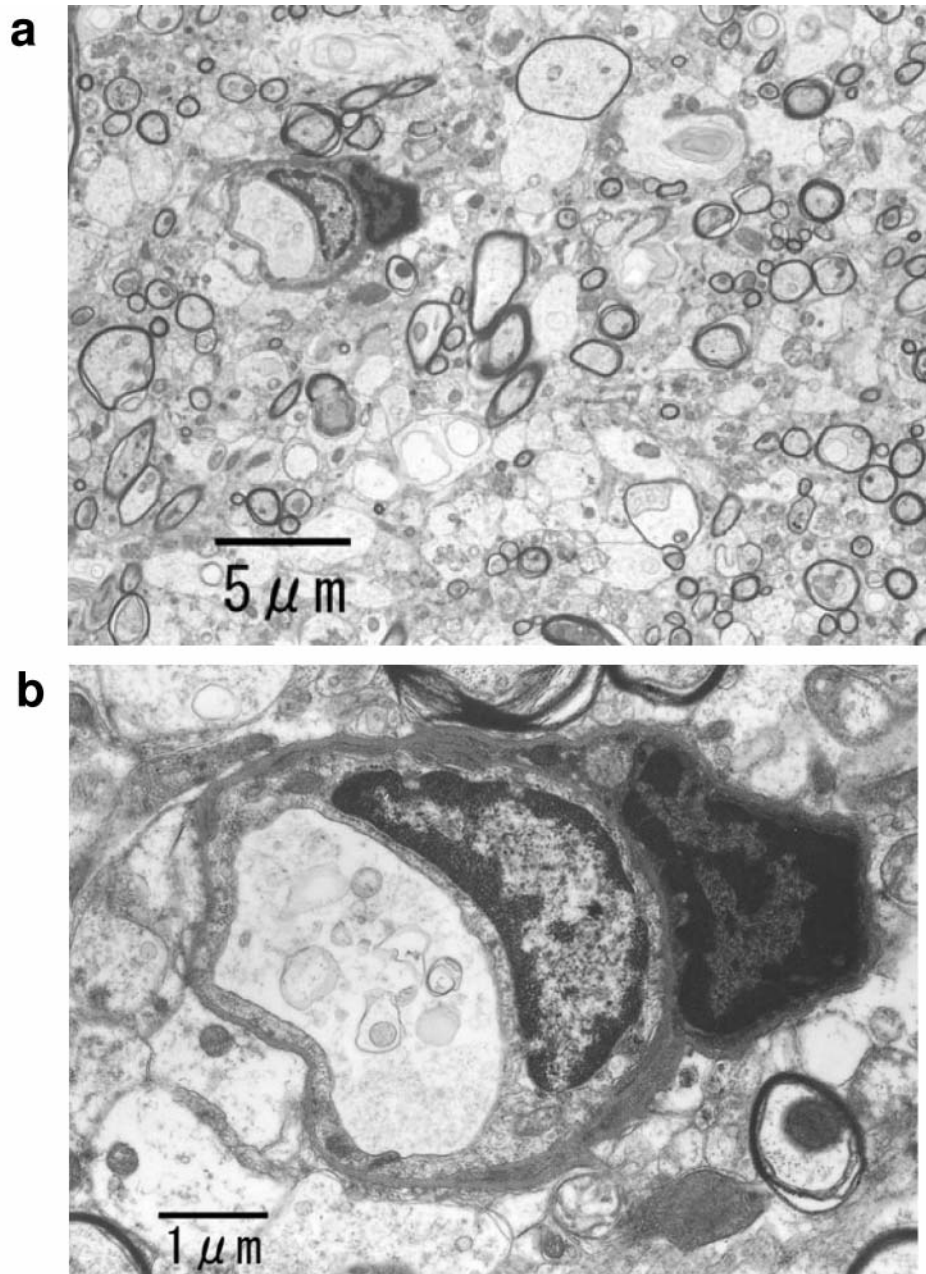


Figure 2. Electron-microscope images of ultrasound-irradiated rat brain. a) No marked difference from unirradiated brain except swelling of astrocytic processes (A). V: capillary  $\times 4400$ ; b) A capillary. No marked difference is found in the structure of the endothelium (E) as compared with normal brain. A: A process of an astrocyte, B: basement membrane, P: pericyte,  $\times 20,000$ .

## Discussion

The BBB limits transfer of materials from the blood into the brain and maintains a stable environment in the brain (15-18). However, this normally protective property of the BBB interferes with passage of drugs into infiltrative malignant tumor cells in the brain in treatment of malignant gliomas.

Methods of opening the BBB anatomically or functionally and to thus transport therapeutic agents into neoplastic cells have therefore been investigated in animal experiments (16, 18, 19). Such agents include hypertonic solutions such as mannitol, protein catabolic enzymes such as streptokinase, histamine, and cobra poison. X-irradiation has also been used for this purpose (16).

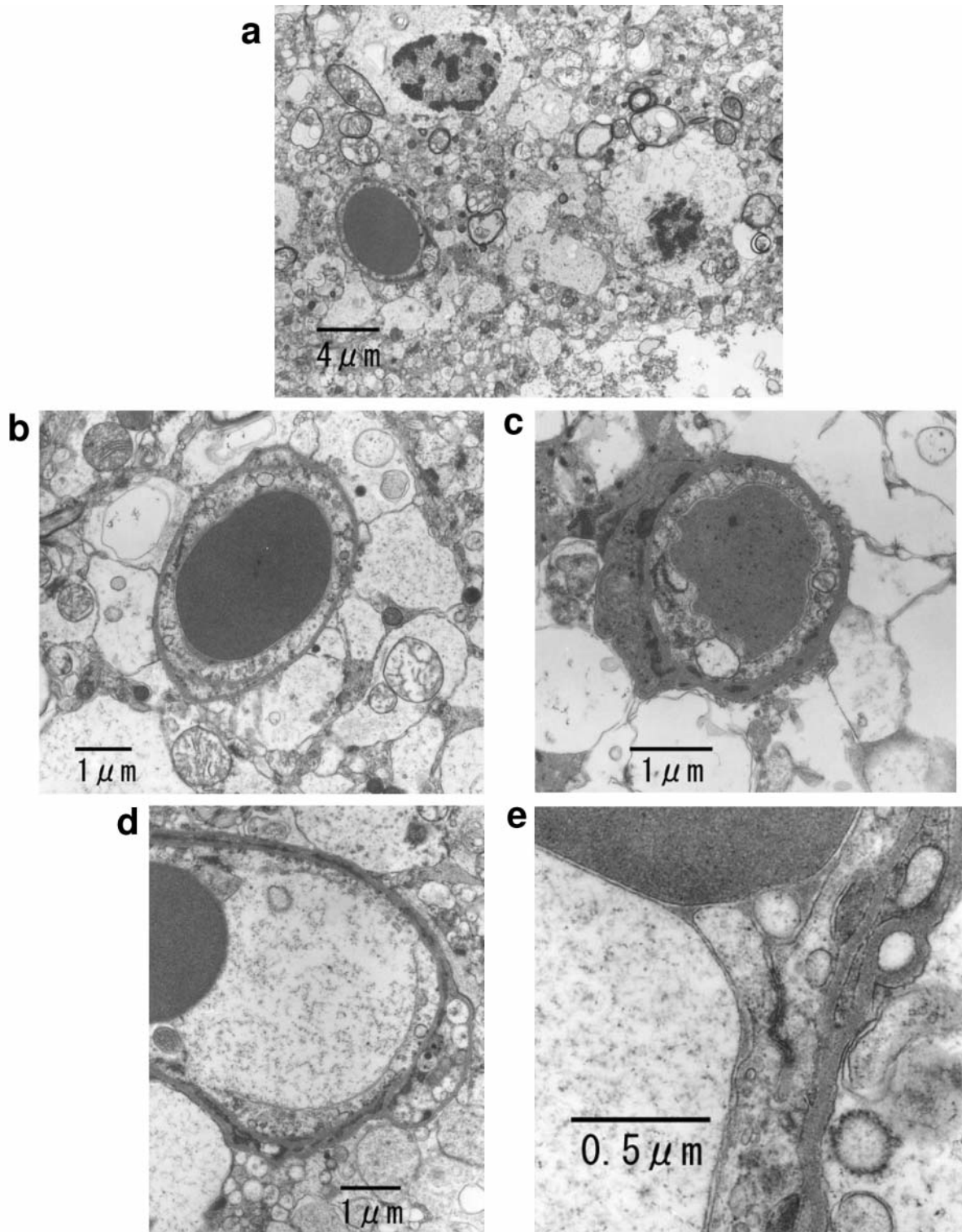


Figure 3. Electron-microscope images of ultrasound-irradiated rat brain with Rose Bengal. a) Processes of astrocytes and nerve cells are swollen. A degenerated cell (\*) is observed. V: capillary,  $\times 6,800$ ; b) A capillary and neighboring structure. Capillary endothelial cells are surrounded by basement membrane and processes of astrocytes (A). B: Basement membrane, E: a capillary endothelium, M: mitochondria,  $\times 14,000$ . c) Cross-section of capillary. A: Process of an astrocyte, B: basement membrane, E: capillary endothelium, M: Mitochondria, P: pericyte, arrow: tight junction,  $\times 26,000$ ; d) Disruption of the cell membrane is seen in the capillary endothelium (E). A: Process of an astrocyte,  $\times 17,000$ ; e) B: Basement membrane, E: capillary endothelium, arrow: tight junction,  $\times 62,000$ .

The capillaries of the brain normally consist of endothelial cells and their surrounding basement membrane, which are surrounded by astrocytes and their processes, as well as pericytes. There are tight junctions between each endothelial cell, without gaps in the cytoplasm, and pinocytotic vesicles are rarely seen in these endothelial cells (20-23).

The BBB consists of endothelial cell tight junctions, basal lamina, and glial processes, and in it endothelial cells are devoid of fenestrations and exhibit little pinocytosis. The pathway of transport of material through the BBB is thought to involve a cytoplasmic gap route through structures such as tight junctions and an intracytoplasmic route through structures such as pinocytotic vesicles. The transport of specific substances from the blood into the brain is restricted, and chemotherapy has thus been relatively ineffective in the treatment of malignant gliomas. To facilitate the transport of chemotherapeutic agents, it is necessary to open the BBB of selected brain tissue and to protect the rest of the brain by preserving an intact BBB. Mestwala *et al.* reported that high-intensity, focused ultrasound selectively disrupts the BBB by opening capillary endothelial tight junctions in the brain of adult Wistar rats (24), and Hynynen *et al.* reported that low-frequency ultrasound bursts can induce local, reversible disruption of the BBB without undesired long-term effects (25-29).

We have reported that antitumor effects were obtained by sonodynamic therapy using focused ultrasound or low-intensity ultrasound with photosensitizer in both *in vivo* and *in vitro* experiments using experimental rat glioma and malignant glioma cells (14) and that the antitumor effect was significantly enhanced by prior administration of Rose Bengal. We investigated disruption of the BBB by focused ultrasound with Rose Bengal using electron microscopy, and found that swollen processes of astrocytes around capillaries and swollen cytoplasm of endothelial cells, numerous pinocytotic vesicles, and swollen mitochondria were observed in both the central and peripheral zones of lesions resulting from ultrasound irradiation with Rose Bengal, although there were no abnormal structural changes of tight junctions of the endothelial cells. Numerous vesicle-like structures were observed in the capillary endothelial cells, which were rarely present in normal rat brain, indicating that these vesicle-like structures were pinocytotic vesicles, which play a role in increasing BBB permeability from the circulation into the brain, in addition to opening of capillary endothelial cell tight junctions.

This is the first study to demonstrate an increase in pinocytotic vesicles in capillary endothelial cells in addition to disruption of endothelial tight junctions by focused ultrasound with a photosensitizer.

In conclusion, focal cell membrane disruption and an increase in pinocytotic vesicles were observed in capillary endothelial cells with focused ultrasound with administration

of a photosensitizer. These findings suggest an increase in BBB permeability in addition to opening of capillary endothelial cell tight junctions. Sonodynamic therapy might thus be useful for infiltrative malignant glioma.

## References

- 1 Bashir R, Hochberg F and Oot R: Regrowth patterns of glioblastoma multiforme related to planning of interstitial brachytherapy radiation fields. *Neurosurgery* 23: 27-30, 1988.
- 2 Katakura R, Sakurai Y and Yoshimoto T: Clinical results of radiochemotherapy for malignant glioma. *Jpn J Neurosurg (Tokyo) I*: 100-109, 1992.
- 3 The Committee of Brain Tumor Registry of Japan: Report of Brain Tumor Registry of Japan. 8th ed. 1993.
- 4 Tachibana K, Kimura N, Okumura M, Eguchi H and Tachibana S: Enhancement of cell killing of HL-60 cells by ultrasound in the presence of photosensitizing drug Photofrin II. *Cancer Lett* 72: 195-199, 1993.
- 5 Tachibana K, Uchida T, Hisano S and Morioka E: Elimination of adult T-cell leukemia. *Lancet* 349: 325, 1997.
- 6 Umemura S, Kawabata K, Sasaki K, Yumita N, Umemura K and Nishigaki R: Recent advances in sonodynamic approach to cancer therapy. *Ultrasound Sonochemistry* 3: 187-191, 1996.
- 7 Umemura S, Yumita N, Nishigaki R and Umemura K: Mechanism of cell damage by ultrasound in combination with hematoporphyrin. *Jpn J Cancer Res* 81: 962-966, 1990.
- 8 Yumita N, Nishigaki R, Umemura K and Umemura S: Synergistic effect of ultrasound and hematoporphyrin on sarcoma 180. *Jpn J Cancer Res* 81: 304-308, 1990.
- 9 Yumita N, Nishigaki R, Umemura K and Umemura S: Hematoporphyrin as a sensitizer of cell-damaging effect of ultrasound. *Jpn J Cancer Res* 80: 219-222, 1989.
- 10 Mychaskiw G, Badr A. E, Tibbs R, Clower B. R and Zhang J. H: Optison disrupts the blood-brain barrier in rats. *Anesth Analg* 91: 798-803, 2000.
- 11 Tachibana K and Tachibana S: The use of ultrasound for drug delivery. *Endocardiography* 18: 323-328, 2001.
- 12 Miyoshi N, Igarashi S and Riesz P: Evidence against singlet oxygen formation by sonolysis of aqueous oxygen-saturated solutions of hematoporphyrin and rose bengal. The mechanism of sonodynamic therapy. *Ultrason Sonochem* 7: 121-124, 2000.
- 13 Umemura S: The effect of ultrasound for human body. *INNERVISION*. 11: 93-94, 1996 (in Japanese).
- 14 Nonaka M, Fukushima T, Hayashi S, Umemura S and Tachibana K: Sonodynamic therapy. *Sentan-iryō series 6; Nōsinkegeka no Saisentan No. 2. Sentan-iryō Kenkyūsho*, pp. 31-36, 2000 (in Japanese).
- 15 Nagai H and Fukuoka H: Blood-brain barrier. *Clin Neurosci* 2(9): 46-49, 1984 (in Japanese).
- 16 Tomita M: Blood-brain barrier. *Neurosci Rev* 1. Igakushoin, pp. 296-321, 1987 (in Japanese).
- 17 Tsubokawa T: Blood-brain barrier. *Clin Neurosci* 10(5): 18-20, 1992 (in Japanese).
- 18 Kotou A: Blood-brain barrier and endothelium of brain vessels. *Clin Neurosci* 10(7): 64-66, 1992 (in Japanese).
- 19 Maeda T and Hoshino T: Blood-brain barrier and drugs. *Clin Neurosci* 8(11): 24-26, 1990 (in Japanese).



- 20 Gotou T: Brain vessels, choroid plexus and cerebrospinal fluid. *Jintaisoshikigaku Shinkei Asakurashoten*, pp. 163-169, 1984 (in Japanese).
- 21 Kotou A: The characteristics of cerebral blood vessels. *Clin Neurosci* 6(7): 15-17, 1988 (in Japanese).
- 22 Nonomura S: The structure of cerebral blood vessel endothelium. *Clin Neurosci* 10(7): 14-17, 1992 (in Japanese).
- 23 Yoshimoto S: The characteristic of cerebral blood vessel endothelium. *Clin Neurosci* 10(7): 61-63, 1992 (in Japanese).
- 24 Mesiwala AH, Farrell L, Wenzel HJ, Silbergeld DL, Crum LA, Winn HR and Mourad PD: High-intensity focused ultrasound selectively disrupts the blood-brain barrier *in vivo*. *Ultrasound Med Biol* 28: 389-400, 2002.
- 25 Hynynen K, McDannold N, Vykhodtseva N and Jolesz FA: Non-invasive opening of BBB by focused ultrasound. *Acta Neurochir[Suppl]* 86: 555-558, 2003.
- 26 Hynynen K, McDannold N, Sheikov NA, Jolesz FA and Vykhodtseva N: Local and reversible blood-brain barrier disruption by noninvasive focused ultrasound at frequencies suitable for trans-skull sonications. *Neuroimage* 24: 12-20, 2005.
- 27 Hynynen K, McDannold N, Vykhodtseva N, Raymond S, Weissleder R, Jolesz FA and Sheikov NA: Focal disruption of the blood-brain barrier due to 260-kHz ultrasound bursts: a method for molecular imaging and targeted drug delivery. *J Neurosurg* 105: 445-454, 2006.
- 28 Kinishita M, McDannold N, Jolesz F.A and Hynynen K: Noninvasive localized delivery of Herceptin to the mouse brain by MRI-guided focused ultrasound-induced blood-brain barrier disruption. *Proc Natl Acad Sci USA* 103: 11719-11723, 2006.
- 29 McDannold N, Vykhodtseva N and Hynynen K: Use of ultrasound pulses combined with DefinityR for targeted blood-brain barrier disruption: a feasibility study. *Ultrasound Med Biol* 33: 584-590, 2007.

*Received May 28, 2008*

*Revised December 29, 2008*

*Accepted January 19, 2009*