

Celecoxib Induces Regression of Putative Preneoplastic Lesions in Rat Liver

JAIME ARELLANES-ROBLEDO¹, LUCRECIA MÁRQUEZ-ROSADO¹, JULIO ISABEL PÉREZ-CARREÓN¹, SAMIA FATTEL-FAZENDA¹, JESÚS AGUIRRE-GARCÍA² and SAÚL VILLA-TREVIÑO¹

¹*Departamento de Biología Celular, Centro de Investigación y de Estudios Avanzados del IPN (Cinvestav), Av. IPN No. 2508. Col. San Pedro Zacatenco, C.P. 07360, México, DF;*

²*Facultad de Medicina, UNAM y Hospital General de México, O.D., Calle Dr. Balmis No. 148, Col. Doctores, C.P. 06726, México, DF, Mexico*

Abstract. *Background: Celecoxib, a cyclooxygenase-2 (COX-2) inhibitor, may reduce the risk and mortality of certain types of human cancer. The chemopreventive effect of celecoxib on preneoplastic lesions induced by chemical hepatocarcinogenesis was investigated. Materials and Methods: Male Sprague Dawley rats were fed a celecoxib-supplemented diet between days 18 and 26 post-initiation (1500 ppm) and sacrificed on day 26. The effects of celecoxib on proliferation, apoptosis, COX-2 activity and liver function were evaluated by immunohistochemistry, TUNEL assay, enzyme-immunoassay and spectrophotometry, respectively. Results: Celecoxib decreased, in area and number, γ -glutamyltranspeptidase and glutathione S-transferase placental-positive lesions, below levels found after 18 days, by 55.2% and 62.2%, and by 50.5% and 71.1%, respectively, ($p < 0.05$). Celecoxib neither induced apoptosis nor altered the levels of prostaglandin E_2 , bilirubin or alanine aminotransferase in the plasma; however, proliferating cell nuclear antigen and cyclin D1 decreased by 77.7% and 94.9%, respectively, ($p < 0.05$). Conclusion: Celecoxib regresses existing preneoplastic liver lesions through antiproliferative processes, without altering liver function.*

Despite much research, the incidence of hepatic cancer remains high. It is the fifth most common cancer in the world and the fourth most common cause of cancer mortality (1). Therefore, it is of great importance for high risk populations that new drugs, diminishing incidence or preventing the disease, be developed. Current therapeutic

strategies are often inefficient because of their high toxicity, while chemoprevention represents a promising, less aggressive strategy to inhibit carcinoma before invasive tumors develop.

Several lines of research suggest that nonsteroidal anti-inflammatory drugs (NSAIDs) may reduce the risk of and mortality from certain types of human cancer. However, conventional NSAIDs are frequently associated with gastrointestinal side-effects because many are non-selective inhibitors of the 2 isoforms of cyclooxygenase, COX-1 and COX-2, hence they also block COX-1-dependent homeostatic functions. COX enzymes catalyze the synthesis of prostaglandins from arachidonic acid. Despite their structural similarity, both cyclooxygenases are regulated differently. COX-1 inhibition results in certain side-effects, because COX-1 is responsible for maintaining gastric mucosal integrity. COX-2 inhibition, on the other hand, is associated with a decrease in inflammation and neoplasia because these alterations are characterized by increased amounts of COX-2 (2). Thus, COX-2 has become a promising therapeutic target.

Celecoxib is a specific COX-2 inhibitor evaluated and approved by the United States Food and Drug Administration for adjuvant treatment of familial adenomatous polyposis, a syndrome that predisposes individuals to colon cancer (3). The chemopreventive effect of celecoxib has been tested in some *in vivo* experimental models addressing a variety of carcinomas, including those of the urinary bladder, colon, breast, prostate and skin (3-8). In addition, celecoxib has been shown to inhibit *in vitro* proliferation and to induce cell cycle arrest and apoptosis in different ways in several tumor cell types (9-13). Although accumulating evidence indicates that celecoxib acts *via* the COX-2 enzyme, there is also evidence suggesting that the antitumor effects of celecoxib involve COX-2-independent mechanisms (12, 13). In short, the exact molecular mechanisms that account for the chemopreventive effects of celecoxib have not been fully elucidated yet.

Correspondence to: Saúl Villa Treviño, Ph.D., Departamento de Biología Celular, Centro de Investigación y de Estudios Avanzados del IPN (Cinvestav), Av. IPN No. 2508. Col. San Pedro Zacatenco, C.P. 07360, México, DF, Mexico. Tel: +5255-5061-3993, Fax: +5255-5061-3393, e-mail: svilla@cell.cinvestav.mx

Key Words: Celecoxib, chemoprevention, hepatocarcinogenesis, regression.

Our recent laboratory study showed that celecoxib possesses a striking chemopreventive activity that inhibits preneoplastic lesions during hepatocarcinogenesis in rats (14), implying that celecoxib interferes with some metabolic processes that are involved in tumor production. Furthermore, an epidemiological study indicated that long-term celecoxib treatment was associated with significant regression of colorectal polyps in patients with familial adenomatous polyposis (15). However, few *in vivo* experiments have researched the mechanisms of celecoxib in various cancers. Here, the ability of celecoxib to regress existing putative preneoplastic lesions induced by chemical hepatocarcinogenesis was analyzed.

Materials and Methods

Reagents and chemicals. Celecoxib (SC-58635) was prepared from commercial Celebrex capsules by solvent extraction. The identity and purity of the molecule was more than 99.9%, verified by NMR at the Chemistry Department (CINVESTAV-IPN, Mexico City, Mexico). Diet 5001, containing 1500 ppm of celecoxib, was prepared in Purina Test Diet, USA. Diethylnitrosamine (DEN), 2-acetylaminofluorene (2-AAF), γ -glutamyl-4-methoxy-2-naphthylamide (GMNA), glycyl-glycine and Fast Blue BB salt (4-benzoylamino-2,5-diethoxybenzediazonium chloride hemi[zinc chloride] salt) were purchased from Sigma Chemical Co. (St. Louis, MO, USA). The PGE₂ (prostaglandin E₂) enzyme immunoassay kit was purchased from R&D Systems, Inc. (MN, USA). The DeadEnd™ Colorimetric TUNEL System kit was purchased from Promega Corp. (Madison, WI, USA). The primary antibody mouse anti-PCNA (proliferating cell nuclear antigen) (13-3900) was purchased from Zymed (San Francisco, CA, USA), the primary antibody rabbit anti-human-GST-p (glutathione S-transferase placental) (A3600) and LSAB Plus-kid were purchased from DAKO (Carpinteria, CA, USA), the primary antibody rabbit anti-cyclin D1 (BSB2020) was purchased from Bio SB (Santa Barbara, CA, USA) and the Bilirubins kit was purchased from Merck of Mexico.

Animals. Six-week-old male Sprague Dawley rats were purchased from Harlan Industries (Mexico City, México). Throughout the experiment, all rats were fed *ad libitum* and housed in a controlled environment with a 12-h light/dark cycle and a temperature of 23°C.

Experimental procedure. After an acclimatization period of 1 week, the rats were randomized into 4 treatment groups (Figure 1). The C group, non-treated rats, were fed the standard 5001 diet; groups HCT18, HCT26 and HCT26+X received the hepatocarcinogenic treatment (HCT) of the Semple-Roberts modified model (16). Briefly, the rats were initiated with an intraperitoneal injection of 200 mg/kg of body weight of DEN and, 7 days later, 2-AAF was orally administered at 20 mg/kg doses for 3 consecutive days before partial hepatectomy. The HCT18 group was fed the standard diet and the rats were sacrificed on day 18 after initiation of the carcinogenic protocol, serving as the reference group of the onset of celecoxib administration. The HCT26 group was fed the standard diet and served as the reference group of the end of celecoxib administration. The HCT26+X group was fed the

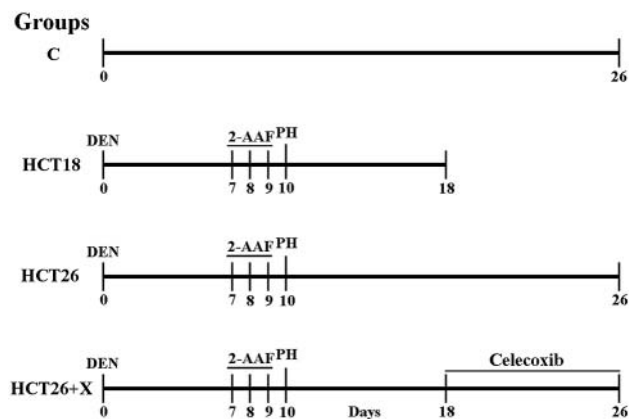


Figure 1. Schematic representation of HCT and celecoxib administration. C group, 5 rats; HCT18 group, 8 rats; HCT26 group, 8 rats; HCT26+X group, 9 rats.

celecoxib-supplemented diet (1500 ppm) between days 18 and 26 post-initiation of the carcinogenic protocol. Rats from groups C, HCT26 and HCT26+X were sacrificed on day 26. Celecoxib was administered between days 18 and 26 post-initiation of the HCT because we had previously observed a well defined linear increase of both the number and area of the putative preneoplastic lesions in the rat liver until the fourth week post-initiation. The animals were monitored daily for general health as well as for food consumption, while their body weight was recorded daily throughout the experiment. The animals were sacrificed under ether anesthesia. At the time of sacrifice, blood was collected by cardiac puncture from all the rats in each group. The blood plasma was quickly frozen in liquid nitrogen and stored at -75°C until analysis. Liver samples were taken from all the animals and prepared as follows: half of each liver was fixed in 10% buffered formalin and the other half was immediately frozen in liquid nitrogen and stored at -75°C . For histological evaluation, formalin-fixed tissues were embedded in paraffin blocks, cut at 4 μm and processed by routine histological methods with hematoxylin-eosin (H&E) staining.

GGT histochemical staining. The putative preneoplastic lesions in rat livers were observed by detection of γ -glutamyl-transpeptidase (GGT) activity as described by Rutenburg *et al.* (17). Briefly, 20- μm frozen liver tissue sections were fixed in absolute ethanol for 10 min at -20°C , followed by addition of GMNA, glycyl-glycine and Fast Blue BB salt in Tris base (100 mM) solution over 30 min at room temperature. Next, the staining was fixed with cupric sulfate for 2 min. Finally, the images of liver tissue were captured with a digital camera mounted on a microscope and the GGT-positive lesions were quantified by image analysis software (analySIS Soft Imaging System GmbH).

Determination of plasma prostaglandin E₂ levels. The blood was collected in heparinized tubes and centrifuged. The upper plasma layer was removed and added to 10 $\mu\text{g/ml}$ of indomethacin, frozen and stored at -75°C . The PGE₂ levels were measured in rat blood plasma using a PGE₂ enzyme

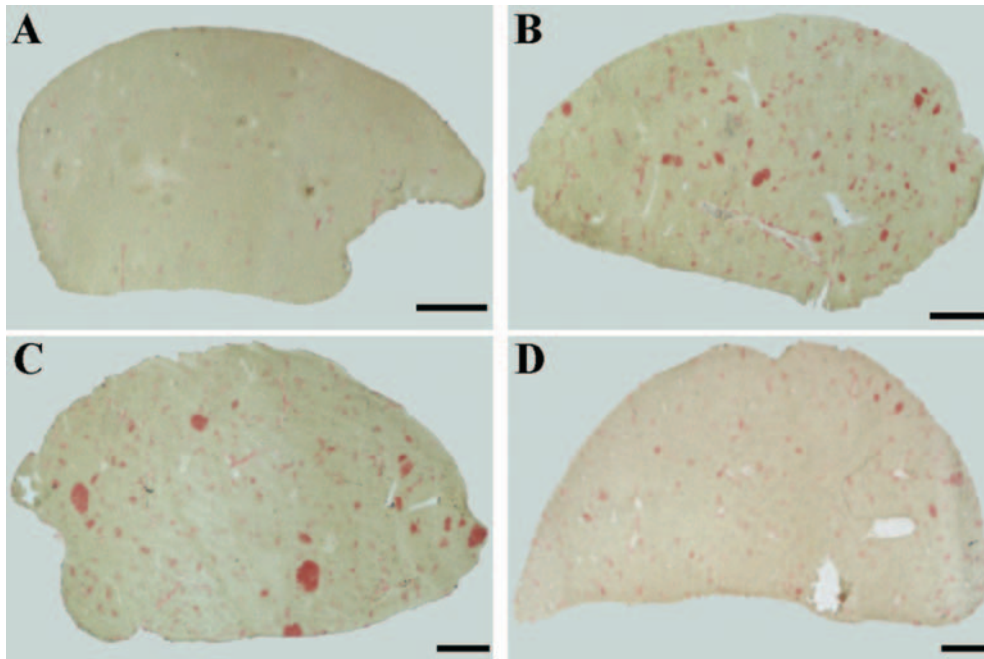


Figure 2. Histochemically-stained sections showing the effect of celecoxib on GGT-positive lesions. Representative liver sections of each treatment. (A) C group, (B) HCT18 group, (C) HCT26 group and (D) HCT26+X group. Tissues of rats fed a celecoxib-supplemented diet showed GGT-positive lesions smaller than tissues from rats fed on a standard diet, including those that were sacrificed at day 18. Scale bars, 2 mm.

immunoassay kit, according to the manufacturer's instructions. The PGE₂ concentration was calculated using the standard curve. All assays were performed in duplicate.

Apoptosis detection by the TUNEL assay. Sections of liver tissues 4 μ m thick were deparaffinized and hydrated gradually. Apoptosis was determined by the DeadEnd™ Colorimetric TUNEL System kit, according to the manufacturer's instructions. The tissues were evaluated under optical microscopy.

Immunohistochemical analysis. Liver tissues embedded in paraffin were sectioned at 4 μ m. The sections were deparaffinized and hydrated gradually. Antigens were unmasked by immersing the sections in 0.1 M sodium citrate buffer (pH 6) and then processing in heat in a water bath for 15 min. Endogenous peroxidase activity was blocked with 0.3% hydrogen peroxide in methanol followed by incubation for 1 h with the primary antibody mouse anti-PCNA, rabbit anti-human-GST-p or rabbit anti-cyclin D1 at 1:100, 1:50 and 1:20 dilution, respectively. A standard staining protocol, using the LSAB Plus-kid according to the manufacturer's instructions, followed. As a positive control for PCNA and cyclin D1, liver sections of one rat subjected to partial hepatectomy and sacrificed after 24 h were used to observe a high proliferation index. Finally, sections were lightly counterstained with hematoxylin, dehydrated and mounted. Under optical microscopy (Olympus 1X70), representative images were captured and then evaluated and quantified by analySIS Soft Imaging System GmbH. For PCNA and cyclin D1, the quantification was performed in 8 randomly-selected fields (X100) per individual sample and the number of positive

nuclei/mm² was calculated. GST-p-positive lesions were quantified similarly to GGT-positive lesions.

ALT activity and bilirubin determination in plasma. Both tests were performed on rat blood plasma; alanine aminotransferase (ALT) activity was measured using the protocol described by Reiman and Frankel (18) and bilirubin was carried out as determined with the Bilirubins kit, according to the manufacturer's instructions. Both assays were performed in duplicate.

Classification of liver lesions. Liver lesions were histologically classified according to Stewart *et al.* (19).

Statistical analysis. For all statistical analyses the Student's *t*-test was used. Data were expressed as mean \pm standard error (SE). In all cases, a difference was considered significant when $p < 0.05$.

Results

Effect of celecoxib on relative liver weight. The relative liver weight of rats treated either with HCT or HCT plus celecoxib were not different at the end of the experimental protocol (data not shown).

Celecoxib regresses putative preneoplastic lesions. Animals that received the HCT were fed either a standard diet or a celecoxib-supplemented diet. Rats treated with HCT plus celecoxib, between days 18 and 26 post-initiation of the HCT, showed GGT-positive lesions smaller in number and area

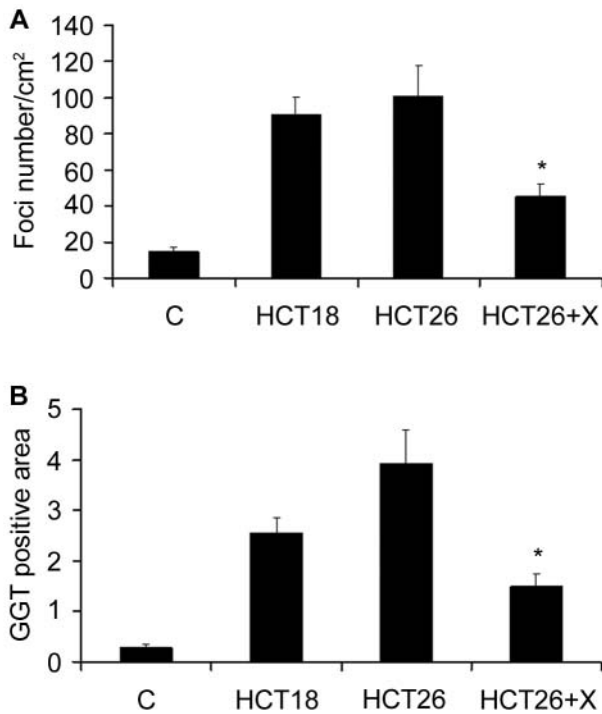


Figure 3. Number and area of GGT-positive lesions in rat liver after celecoxib administration. (A) GGT-positive lesion number/cm², *statistically different from the HCT18 and HCT26 groups, $p < 0.05$. (B) GGT-positive area percent with respect to total tissue, *statistically different from HCT26 group, $p < 0.05$. Three liver histological sections per rat from each group were randomly chosen and analyzed. C group (rats=5), HCT18 group (rats=8), HCT26 group (rats=8) and HCT26+X group (rats=9). Results are expressed as means \pm SE.

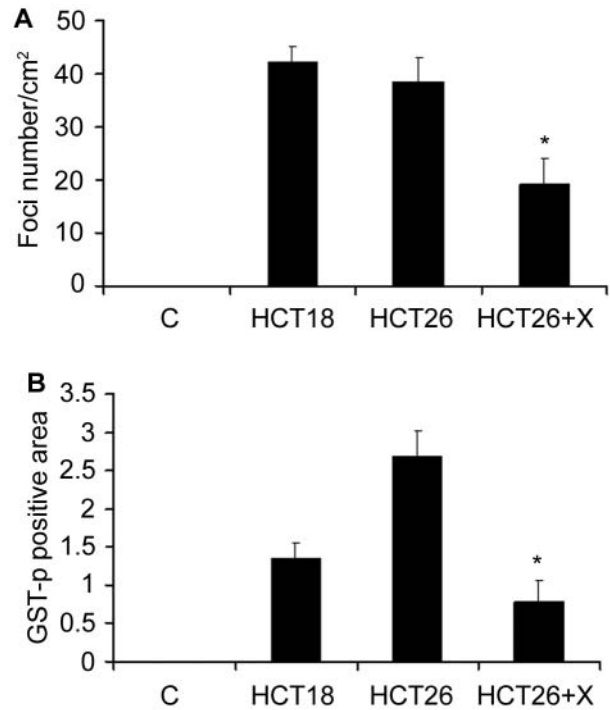


Figure 4. Number and area of GST-p-positive lesions in rat liver after celecoxib administration. (A) GST-p-positive lesions number/cm², *statistically different from the HCT18 and HCT26 groups, $p < 0.05$. (B) GST-p-positive area percent with respect to total tissue, *statistically different from HCT26 group, $p < 0.05$. Two liver histological sections per rat from each group were randomly chosen and analyzed. C group (rats=3), HCT18 group (rats=3), HCT26 group (rats=3) and HCT26+X group (rats=4). Results are expressed as means \pm SE.

(Figure 2D) than rats subjected to HCT alone (Figure 2C). As shown in Figures 3A and 3B, both the number and area of GGT-positive lesions, were significantly reduced by 55.2% ($p=0.003$) and 62.2% ($p < 0.001$), respectively. Likewise, number and area of GST-p-positive lesions were reduced by 50.5% ($p=0.02$) and 71.1% ($p=0.004$) respectively (Figures 4A and 4B). When these results were compared with rats sacrificed on day 18 post-initiation, a similar reduction in the number of GGT- and GST-p-positive lesions, by 50.0% ($p=0.005$) and 54.7% ($p=0.02$), respectively, was seen. The lesion quantification detection parameter was more than 0.01 mm². Our results clearly indicate that celecoxib reverted the existing putative preneoplastic lesions in hepatocarcinogenesis.

Celecoxib did not inhibit COX-2 activity. A progressive increase in plasma PGE₂ levels associated with disease progression has been shown in cancer patients (20). This phenomenon prompted us to evaluate the effect of celecoxib on PGE₂ levels in rats fed with the celecoxib-supplemented diet in our experimental model. COX-2

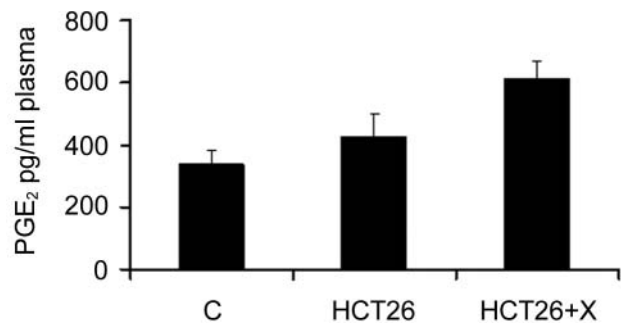


Figure 5. Determination of prostaglandin E₂ levels in plasma of rats. PGE₂ levels in the plasma of rats fed a celecoxib-supplemented diet are expressed as the mean value performed in duplicate assays of 3 rats per group \pm SE. The data were not significantly different from the HCT26 group, $p > 0.05$.

activity was evaluated by analysis of PGE₂ levels in the plasma. In concordance with previous reports (8, 21), the rats treated with HCT plus celecoxib did not show a statistically significant change (Figure 5).

Celecoxib did not induce apoptosis in the development of putative preneoplastic lesions. The TUNEL assay was used to evaluate the effect of celecoxib on apoptosis of altered cells. Representative histological sections of each treatment are depicted in Figure 6. Neither the rats that received HCT alone (Figure 6C) nor the rats subjected to HCT plus celecoxib (Figure 6D) showed apoptotic nuclei, compared with the positive controls (Figure 6A); at the time tested, the results were similar to the negative control (Figure 6B). The same results were obtained in sacrificed rats on day 18 post-initiation (image not shown). These results showed that the celecoxib administration for 8 days did not induce apoptotic processes in the hepatocarcinogenic model.

Celecoxib inhibits cell proliferation during development of hepatocarcinogenesis. Representative histological sections of each treatment are presented in Figure 7. The positive label of PCNA was detected in most cells that were in mitosis or cellular division (arrows in Figure 7B). The quantitative analysis of the different treatments is shown in Figure 7D. The rats treated with HCT plus celecoxib showed a 77.7% ($p=0.02$) reduction of PCNA-positive nuclei (Figure 7C), compared with the rats subjected to HCT alone (Figure 7B). These results indicated that the regression produced by celecoxib of the putative preneoplastic lesions in the rat liver was induced by inhibition of proliferation.

Subsequently, whether the PCNA protein expression observed in rats subjected to HCT was limited to the putative preneoplastic lesions area and whether the reduction in its expression after celecoxib treatment was only within these lesions due to the proliferation inhibition of the altered cell, was determined. By immunostaining, GST-p and PCNA expressions in liver serial sections were analyzed. As shown in Figure 8B, although PCNA-positive nuclei were observed in whole tissue of the rats subjected to HCT, the PCNA-positive nuclei number was higher within GST-p-positive lesions than in the surrounding tissue, *i.e.* 655 PCNA-positive nuclei/mm² versus 280 PCNA-positive nuclei/mm² (Table I). Representative liver sections of a GST-p-positive area (Figure 8A) and with high PCNA expression (Figure 8B), of rats subjected to HCT, are shown. Interestingly, the PCNA-positive label was more intense in the nuclei of hepatocytes situated at the inside limit of the lesions (arrows in Figure 8B). In the tissue of rats treated with HCT plus celecoxib (Figure 8C and 8D), PCNA expression was observed within and outside the lesions (Figure 8D) compared with the tissue of rats subjected to HCT, where expression was less in both locations, 330 PCNA-positive nuclei/mm² versus 68 PCNA-positive nuclei/mm², Table I. Differences between the HCT and HCT plus celecoxib groups were statistically significant both in the lesions and in surrounding tissue (49.6%, $p=0.04$ and 75.7%, $p<0.001$, respectively). In the whole tissue, the difference was 57.5% $p=0.003$. It is noteworthy that PCNA

expression was mostly observed in the GST-p-positive lesions and the reduction of its expression in whole tissue was correlated with a decrease in number and size of the putative preneoplastic lesions.

To determine the underlying mechanism of proliferation inhibition mediated by celecoxib, its effect on cyclin D1 expression, a cell cycle regulator protein responsible for the transition from G₁- to S-phase in both normal regulation of the cell cycle and development of human cancers (22), was investigated. Similarly to PCNA expression, the coexistence of GST-p and cyclin D1 expression in liver serial sections was analyzed. As shown in Figure 9, the expression of cyclin D1 was similar to PCNA. Cyclin D1-positive nuclei were observed in whole tissue of both the HCT and HCT plus celecoxib groups; in both, the cyclin D1-positive nuclei number was higher within GST-p-positive lesions than in the surrounding tissue (Table II). Differences were statistically significant between the HCT and HCT plus celecoxib groups, both in the lesions and in surrounding tissue by 94.5%, $p<0.001$ and 96.7% $p<0.001$, respectively, while in the whole tissue the difference was 94.9%, $p<0.001$. Together, these results indicated that celecoxib inhibited cell cycle progression.

Celecoxib does not alter liver function. The hepatic side-effects induced by celecoxib were investigated by evaluating liver function using 2 general toxicological liver tests, bilirubin determination and alanine aminotransferase (ALT) activity in rat plasma, and through H&E histopathological examination. A significant increase of ALT activity in the HCT26 group compared with the control group can be seen in Table III, indicating that the carcinogenic treatment altered ALT activity. However, a significant reduction of 19.3% (22.9 $\mu\text{mol/l/min}$; $p<0.05$) of the activity of this enzyme was observed in the rats treated with HCT plus celecoxib compared with the group that only received HCT (28.3 $\mu\text{mol/l/min}$). Total bilirubin levels increased in the rats treated with HCT plus celecoxib (12.3 $\mu\text{mol/l}$) compared with rats subjected to HCT alone (8.5 $\mu\text{mol/l}$), but with no statistical difference. On the other hand, H&E histopathological analysis showed distortion of the liver tissue in animals subjected to HCT, while in animals treated with HCT plus celecoxib, tissue distortion almost disappeared (image not shown). Together, these results suggest that celecoxib did not induce alterations in liver function in addition to those induced by the HCT.

Discussion

It has been shown that conventional NSAIDs inhibit the growth of several human cancers. These drugs are associated with gastric side-effects produced by inhibition of both COX isoforms, COX-1 and COX-2. Celecoxib belongs to a generation of NSAIDs that selectively inhibit COX-2. Previous studies have shown the anticancer effect of celecoxib

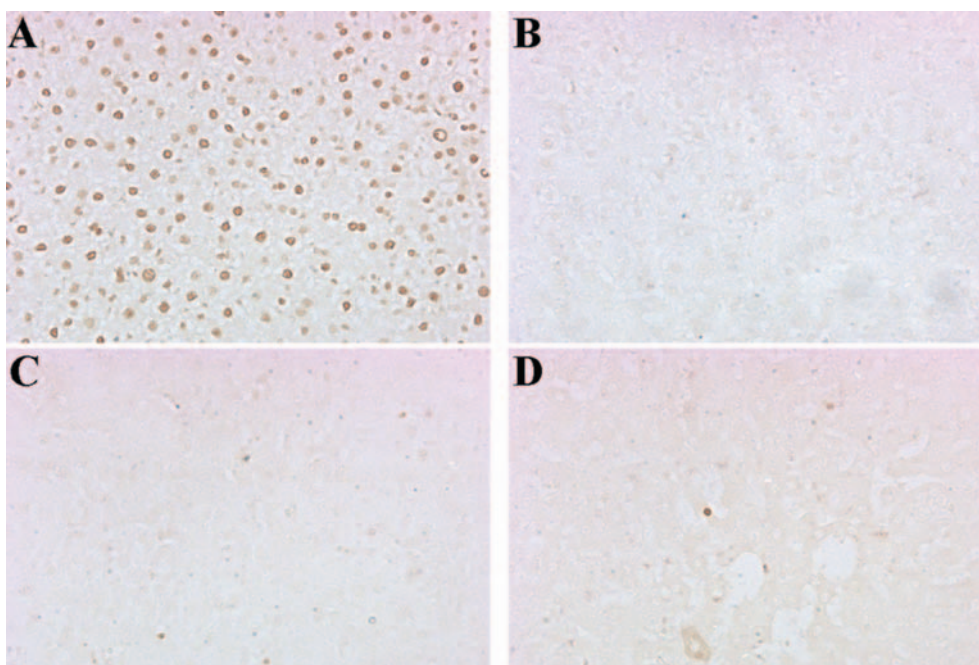


Figure 6. Effect of celecoxib on apoptosis induction in the hepatocarcinogenic model. Liver sections representative of each treatment are presented. (A) Positive control, tissue treated with DNase. (B) Negative control tissue. (C) HCT26 tissue. (D) HCT26+X tissue. These images show that celecoxib administration from days 18 to 26 did not induce apoptotic processes in the hepatocarcinogenic model. Four rats were evaluated for each group; the assay was performed in 2 independent experiments. Magnification X200.

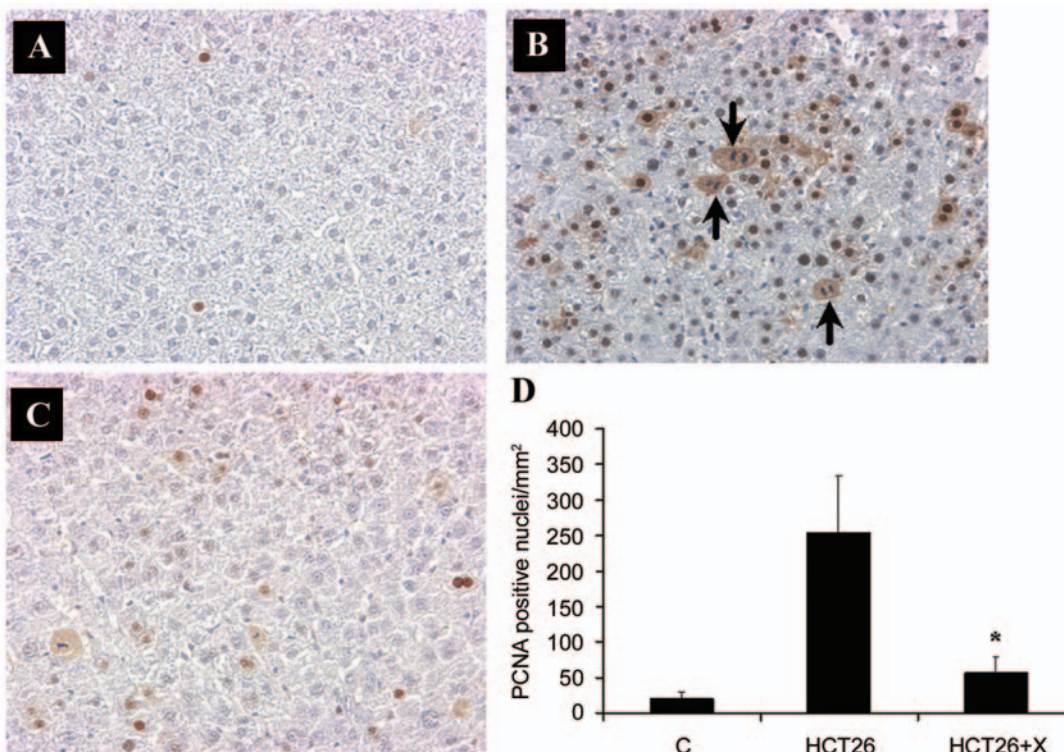


Figure 7. Effect of celecoxib on cell proliferation in the hepatocarcinogenic model. PCNA expression was reduced by celecoxib administration. The images are representative of each treatment. (A) C group, n=3. (B) HCT26 group, n=3. (C) HCT26+X group, n=5. (D) Quantification of PCNA-positive nuclei. Quantification was performed by measuring 10 fields (X100) randomly selected per individual sample. The immunohistochemical analysis was performed in 2 independent experiments. Positive and isotype controls were included in each experiment. Images were captured to a magnification of X200. The results are expressed as means \pm SE. *Statistically different from the HCT26 group, $p < 0.05$. The arrows show cellular division.

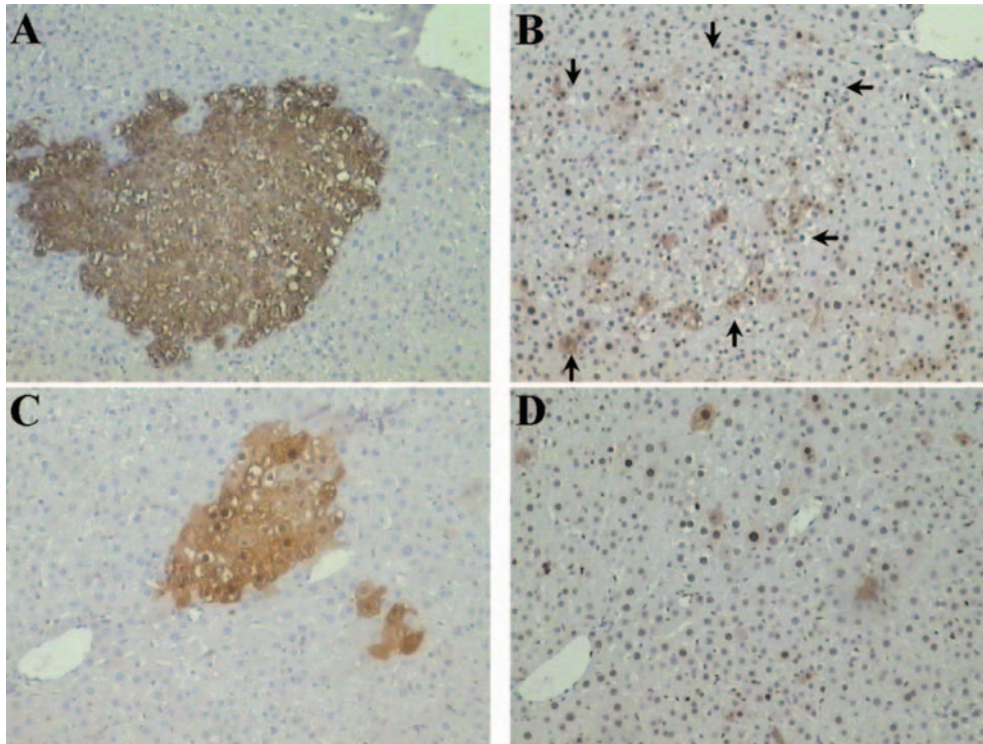


Figure 8. Serial liver sections stained for GST-p and PCNA. A and B, liver sections from rats subjected to HCT; C and D, liver sections from rats subjected to HCT plus celecoxib; A and C, stained for GST-p and B and D, stained for PCNA. Arrows in B show the limit of the lesions extrapolated in A. Magnification X100.

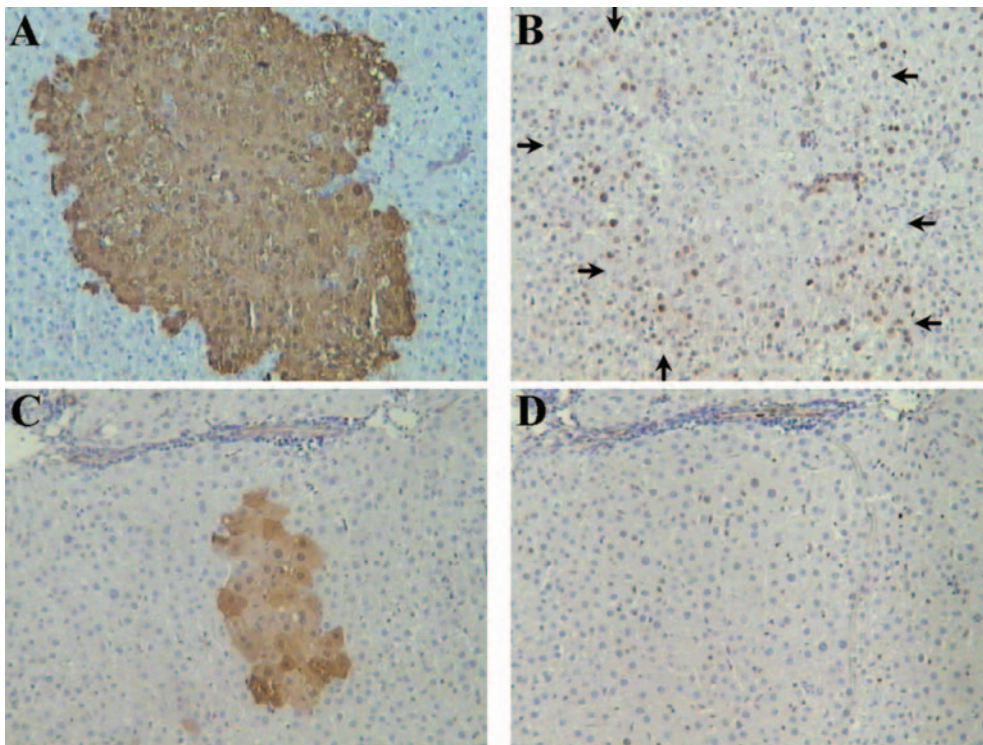


Figure 9. Serial liver sections stained for GST-p and cyclin D1. A and B, liver sections from rats subjected to HCT; C and D, liver sections from rats subjected to HCT plus celecoxib; A and C, stained for GST-p and B and D, stained for cyclin D1. Arrows in B show the limit of the lesions extrapolated in A. Magnification X100.

Table I. PCNA expression within and surrounding GST-p-positive lesions.

Treatment group	PCNA-positive nuclei number/mm ² *		
	Within lesions	Surrounding tissue	Whole tissue
Control	---	---	20.86±8.13
HCT26	655±127	280±42	934.91±131.26
HCT26+X	330±68 ^a	68±11 ^b	397.57±73.56

*Means±SE of quantification of 8 X 100 fields per rat, n=3.

^aStatistically different PCNA-positive nuclei number within lesions in the HCT26 group.

^bStatistically different PCNA-positive nuclei number in the surrounding tissue in the HCT26 group; *p*<0.05.

in several cancer cell lines, including liver cancer (9-13), as well as in *in vivo* experimental carcinogenesis models induced both chemically and genetically (3-7). Studies from our laboratory have shown that celecoxib prevents the development of preneoplastic lesions (14), but there are no reports indicating the antitumor activity of celecoxib on the regression of existing liver preneoplastic lesions in rats, a complex and totally different prevention phenomenon. To distinguish prevention from regression effects, the rats were treated with the hepatocarcinogenic protocol and, after putative preneoplastic lesions had been established, celecoxib was administered, when the increase of both the number and area of these lesions was still linear. Our results showed that celecoxib regressed GGT- and GST-p-positive lesions in both number and area, reaching levels below those measured at the onset of treatment. These results indicated that celecoxib reverted the existing putative preneoplastic lesions in hepatocarcinogenesis in concordance with its ability shown in other chemical carcinogenesis models (4, 6, 7).

COX-2 is an inducible isoform which converts free arachidonic acid to prostaglandins (23). In a prostate cancer experimental model and in brain cancer patients, an increase in plasma PGE₂ levels was associated with disease progression (3, 20). Thus, a logical explanation of the celecoxib effect would be that COX-2 inhibition leads to a reduction in PGE₂ levels. However, our results indicated that celecoxib did not decrease the PGE₂ levels in plasma. These findings are in agreement with two reports of UVB-induced skin cancer in murine models. In the first case, celecoxib was administered in the diet (21); in the second, celecoxib was administered topically (8). In both cases celecoxib showed clear anticancer properties, but the PGE₂ levels were not diminished. Contrary to this information, in a xenograft tumor model in rodent cornea, celecoxib showed anticancer properties associated with a significant decrease in PGE₂ levels (24). In spite of the latter, most data suggest that the chemopreventive activity of celecoxib is exerted by a pathway other than PGE₂ reduction.

Table II. Cyclin D1 expression within and surrounding GST-p-positive lesions.

Treatment group	Cyclin D1-positive nuclei number/mm ² *		
	Within lesions	Surrounding tissue	Whole tissue
Control	---	---	---
HCT26	548.4±102.5	136.7±15.35	685.08±102.46
HCT26+X	30.4±11.0a	4.5±1.6b	34.87±11.45

*Means±SE of quantification of 8 X 100 fields per rat, n=3.

^aStatistically different cyclin D1-positive nuclei number within lesions in the HCT26 group.

^bStatistically different cyclin D1-positive nuclei number in the surrounding tissue in the HCT26 group; *p*<0.05.

Table III. Bilirubin and ALT determinations.

Treatment group	n	ALT (µmol/l/min)*	Bilirubin (µmol/l)*
Control	5	16.4±0.5	8.1±0.2
HCT26	8	28.3±1.3	8.5±1.1
HCT26+X	9	22.9±1.3 ^a	12.3±1.2

*Means±SE of one experiment performed in duplicate.

^aALT activity decreased compared with the HCT26 group; *p*<0.05.

Furthermore, it must be considered whether PGE₂ production is also inhibited by celecoxib at others stages of liver cancer development characterized by high COX-2 activity.

One feature of cancer is its continuous growth, and this event is associated with an increase in cell proliferation and a loss of apoptotic mechanisms (25). Studies have shown that celecoxib induces apoptosis in cancer cell lines (9-13). Despite these reports, the findings in the current study were different. It was found that celecoxib did not induce apoptosis in developing putative preneoplastic lesions. This is in agreement with a previous report from our laboratory, when celecoxib was administered before and during the HCT by 35 days. The apoptosis phenomenon was examined at different points of this period using four different procedures, but was not found (14). From these results, we consider that there is a close relationship between the absence of the inhibition of PGE₂ production and of apoptosis induction, since it has been reported elsewhere, both in *in vivo* colon cancer models, that celecoxib did not induce apoptosis (26) and that the presence of PGE₂ reduced this phenomenon (27). Thus, the absence of apoptosis could be due to cell cycle arrest. This is also supported by a study in cholangiocarcinoma cell lines, in which the exogenous administration of PGE₂ partially prevented the celecoxib-mediated inhibition of cell growth (28).

We studied the expression of PCNA, a nuclear protein required for DNA synthesis (29) and cyclin D1 expression, a cell cycle regulator protein responsible for the transition from G₁- to S-phase (22), since it has been shown that celecoxib inhibited proliferation in cancer cell lines (9, 10). In agreement with these data, we showed that celecoxib drastically decreased both the PCNA and cyclin D1 expressions. These findings indicate that the proteins that participate in cell cycle progression can be targeted for chemoprevention of hepatocellular carcinoma (HCC) and that celecoxib may play an important role in cell cycle progression and DNA synthesis. This activity has also been observed in a xenograft pancreatic mouse tumor model, where celecoxib inhibited cell growth by inducing a G1 cell cycle block and reducing DNA synthesis (30). This clear effect of celecoxib on the development of putative preneoplastic lesions suggests that it is related to cell cycle arrest and indicates that the regression of lesions involved antiproliferative mechanisms induced by celecoxib. We also investigated whether PCNA and cyclin D1 expressions were limited to the GST-p-positive lesion area. GST-p was selected for this determination since it has been shown that it is the best marker to identify putative preneoplastic lesions (31). Hepatocyte proliferation was mostly seen within lesions, although this phenomenon suggests that the hepatocyte proliferation induced with DEN and 2AAF was chiefly induced inside the putative preneoplastic lesions, it also exists in the surrounding tissue, at least in the first 4 weeks of carcinogenesis. The larger reduction of cyclin D1 expression than that of PCNA suggests that the effect of celecoxib was more specific to cell cycle progression than to DNA synthesis. Therefore, the inhibitory effect of celecoxib on the development of the GST-p-positive lesions was linked to the inhibition of proliferation through inhibition of cell cycle progression, including the surrounding tissue.

It is important to thoroughly test the toxicity of any selected chemopreventive drug. Little is known regarding celecoxib toxicity at the level of liver injury. However, some reports indicated that this drug has a protective effect against liver injury (32, 33). We evaluated the liver function with two liver injury tests, bilirubin determination and ALT activity in rat plasma, and with H&E histopathological analysis. None of the liver injury tests nor the histological analysis showed important changes induced by celecoxib. Since the ALT level was significantly decreased in animals treated with celecoxib, we suggest that, although celecoxib was administered short-term, the ALT level is an indicator of an underlying alteration that also plays a role in the development of putative preneoplastic lesions. The finding that high ATL levels are associated with the rapid development of HCC in early stage hepatitis C virus-associated cirrhosis (34) supports

this suggestion. In this study, it was demonstrated that celecoxib administered for a short period did not induce alterations in liver function and structure. Future long-term studies will be necessary to determine the effect of celecoxib on rat liver function.

Our results open the possibility of a comparative study between the rat HCC induced with DEN and 2-AAF and the human HCC behavior. In a recent study, a cross-species comparison of gene expression patterns of HCC identified mouse liver tumors induced with DEN similar to those of the poorer survival group of human HCC, thus, allowing for an extrapolation of the effect of the drug evaluated (35).

In summary, our results demonstrated that the regression of GGT- and GST-p-positive lesions, induced by celecoxib in a chemical hepatocarcinogenesis model, was associated with antiproliferative process activation and that this COX-2 inhibitor might be an effective agent against hepatocarcinogenesis. In addition, these findings also motivate the establishment of long-term studies to further define the chemopreventive effectiveness of celecoxib on liver tumor development.

Acknowledgements

This work was supported by grant 39525-M from CONACYT, México and a fellowship from CONACYT to J.A.R.; 173787 (2002-2004). We thank Dr. A. Flores for help in celecoxib purification; Dr. P. Muriel for providing reagents to bilirubin and the ALT determination; E. Arce-Popoca, S. Hernández-García, L. Alemán-Lazarini, M. Moreno-Pérez and R. Hernández-Guadarrama for their excellent technical assistance. We also express our gratitude to Dr. J. Fernández, R. Leyva-Muñoz, R. Gaxiola-Centeno and M. Flores-Cano for their technical support at the Animal House and to I. Pérez-Montfort for correcting the manuscript.

References

- 1 McGlynn KA, Tsao L, Hsing AW, Devesa SS and Fraumeni JF Jr: International trends patterns of primary liver cancer. *Int J Cancer* 94: 290-296, 2001.
- 2 Subbaramaiah K and Dannenberg AJ: Cyclooxygenase 2: a molecular target for cancer prevention and treatment. *Trends Pharmacol Sci* 24: 96-102, 2003.
- 3 Gupta S, Adhami VM, Subbarayan M, MacLennan GT, Lewin JS, Hafeli UO, Fu P and Mukhtar H: Suppression of prostate carcinogenesis by dietary supplementation of celecoxib in transgenic adenocarcinoma of the mouse prostate model. *Cancer Res* 64: 3334-3343, 2004.
- 4 Grubbs CJ, Lubet RA, Koki AT, Leahy KM, Masferrer JL, Steel VE, Kelloff GL, Hill DL and Seibert K: Celecoxib inhibits N-butyl-N-(4-hydroxybutyl)-nitrosamine-induced urinary bladder cancers in male B6D2F1 mice and female Fisher-344 rats. *Cancer Res* 60: 5599-5602, 2000.
- 5 Jacoby RF, Seibert K, Cole CE, Kelloff G and Lubet RA: The cyclooxygenase-2 inhibitor celecoxib is a potent preventive and therapeutic agent in the min mouse model of adenomatous polyposis. *Cancer Res* 60: 5040-5044, 2000.

- 6 Reddy BS, Hirose Y, Lubet R, Steele V, Kelloff G, Paulson S, Seibert K and Rao CV: Chemoprevention of colon cancer by specific cyclooxygenase-2 inhibitor, celecoxib, administered during different stages of carcinogenesis. *Cancer Res* 60: 293-297, 2000.
- 7 Harris RE, Alshafie GA, Abou-Issa H and Seibert K: Chemoprevention of breast cancer in rats by celecoxib, a cyclooxygenase 2 inhibitor. *Cancer Res* 60: 2101-2103, 2000.
- 8 Wilgus TA, Koki AT, Zweifel BS, Rubal PA and Oberyszyn TM: Chemotherapeutic efficacy of topical celecoxib in a murine model of ultraviolet light B-induced skin cancer. *Mol Carcinog* 38: 33-39, 2003.
- 9 Wu GS, Zou SQ, Liu ZR, Tang ZH and Wang JH: Celecoxib inhibits proliferation and induces apoptosis *via* prostaglandin E₂ pathway in human cholangiocarcinoma cell lines. *World J Gastroenterol* 9: 1302-1306, 2003.
- 10 Kern MA, Schubert D, Sahi D, Schöneweifs MM, Moll I, Haugg AM, Dienes HP, Breuhahn K and Schirmacher P: Proapoptotic and antiproliferative potential of selective cyclooxygenase-2 inhibitors in human liver tumor cells. *Hepatology* 36: 885-894, 2002.
- 11 Zhang Z, Lai GH and Sirica AE: Celecoxib-induce apoptosis in rat cholangiocarcinoma cells mediated by Akt inactivation and Bax translocation. *Hepatology* 39: 1028-1037, 2004.
- 12 Leng J, Han C, Demetris AJ, Michalopoulos GK and Wu T: Cyclooxygenase-2 promotes hepatocellular carcinoma cell growth through AKT activation: evidence for AKT inhibition in celecoxib-induced apoptosis. *Hepatology* 38: 756-768, 2003.
- 13 Grösch S, Tegeder I, Neiderberger E, Bräutigam L and Geisslinger G: COX-2 independent induction of cell cycle arrest and apoptosis in colon cancer cells by the selective COX-2 inhibitor celecoxib. *FASEB J* 15: 2742-2744, 2001.
- 14 Márquez-Rosado L, Trejo-Solís MC, García-Cuellar C and Villatreviño S: Celecoxib, a cyclooxygenase-2 inhibitor, prevents induction of liver preneoplastic lesions in rats. *J Hepatol* 43: 653-660, 2005.
- 15 Steinbach G, Lynch PM, Phillips RKS, Wallace MH, Hawk E, Gordon GB, Wakabayashi N, Saunders B, Shen Y, Fujimura T, Su LK and Levin B: The effect of celecoxib, a cyclooxygenase-2 inhibitor, in familial adenomatous polyposis. *N Engl J Med* 342: 1946-1952, 2000.
- 16 Semple-Roberts E, Hayes MA, Armstrong D, Becker RA, Raczy WJ and Farber E: Alternative methods of selecting rat hepatocellular nodules resistant to 2-acetylaminofluorene. *Int J Cancer* 40: 643-645, 1987.
- 17 Rutenburg AM, Kim H, Fischbein JW, Hanker JS, Wasserkrug HL and Seligman AM: Histochemical and ultrastructural demonstration of γ -glutamyl transpeptidase activity. *J Histochem Cytochem* 17: 517-526, 1969.
- 18 Reitman S and Frankel S: A colorimetric method for determination of serum oxaloacetic and glutamic pyruvic transaminases. *Am J Clin Pathol* 28: 56-63, 1957.
- 19 Stewart HL, Williams G, Keysser CH, Lombart LS and Montali RJ: Histologic typing of liver tumors of the rat. *J Natl Cancer Inst* 64: 179-206, 1980.
- 20 Loh JK, Hwang SL, Lieu AS, Huang TY and Howng SL: The alteration of prostaglandin E₂ levels in patients with brain tumors before and after tumor removal. *J Neuro-Oncol* 57: 147-150, 2002.
- 21 Won YK, Ong CN, Shi XL and Shen HM: Chemopreventive activity of parthenolide against UVB-induced skin cancer and its mechanisms. *Carcinogenesis* 25: 1449-1458, 2004.
- 22 Donnellan R and Chetty R: Cyclin D1 and human neoplasia. *J Clin Pathol Mol Pathol* 51: 1-7, 1998.
- 23 Williams CS, Mann M and DuBois RN: The role of cyclooxygenases in inflammation, cancer, and development. *Oncogene* 18: 7908-7916, 1999.
- 24 Leahy KM, Ornberg RL, Wang Y, Zweifel BS, Koki AT and Masferrer JL: Cyclooxygenase-2 inhibition by celecoxib reduces proliferation and induces apoptosis in angiogenic endothelial cells *in vivo*. *Cancer Res* 62: 625-631, 2002.
- 25 Hanahan D and Weinberg RA: The hallmarks of cancer. *Cell* 100: 57-70, 2000.
- 26 Williams CS, Watson AJ, Sheng H, Helou R, Shao J and DuBois RN: Celecoxib prevents tumor growth *in vivo* without toxicity to normal gut: lack of correlation between *in vivo* and *in vitro* models. *Cancer Res* 60: 6045-6051, 2000.
- 27 Kawamori T, Uchiya N, Sugimura T and Wayabayashi K: Enhancement of colon carcinogenesis by prostaglandin E₂ administration. *Carcinogenesis* 24: 985-990, 2003.
- 28 Han C, Leng J, Demetris AJ and Wu T: Cyclooxygenase-2 promotes human cholangiocarcinoma growth: evidence for cyclooxygenase-2-independent mechanism in celecoxib-mediated induction of p21^{waf1/cip1} and p27^{kip1} and cell cycle arrest. *Cancer Res* 64: 1369-1374, 2004.
- 29 Kelman Z: PCNA: structure, function and interactions. *Oncogene* 14: 629-640, 1997.
- 30 Patel MI, Subbaramaiah K, Du B, Chang M, Yang P, Newman RA, Cordon-Cardo C, Thaler HT and Dannenberg AJ: Celecoxib inhibits prostate cancer growth: evidence of a cyclooxygenase-2-independent mechanism. *Clin Cancer Res* 11: 1999-2007, 2005.
- 31 Hendrich S, Campbell HA and Pitot HC: Quantitative stereological evaluation of four histochemical markers of altered foci in multistage hepatocarcinogenesis in the rat. *Carcinogenesis* 8: 1245-1250, 1987.
- 32 Yi H, Wang X, Miao JY, Du JP, Pan YL, Liu N, Zhang XM and Fan DM: Protective effect of selective cyclooxygenase-2 inhibitor on alcohol-induced liver injury in rats. *Zhonghua Gan Zang Bing Za Zhi* 11: 663-666, 2003.
- 33 Ensminger W, Knol J, DeRemer S, Wilkinson E, Walker S, Williams D and Maybaum J: Effects of dexamethasone or celecoxib on biliary toxicity after hepatic arterial infusion of 5-fluorodeoxyuridine in a canine model. *Cancer Res* 64: 311-315, 2004.
- 34 Tarao K, Rino Y, Ohkawa S, Shimizu A, Tamai S, Miyzkawa K, Imada T, Shindo K, Okamoto N and Totsuka S: Association between high serum alanine aminotransferase levels and more rapid development and higher rate of incidence of hepatocellular carcinoma in patients with hepatitis C virus-associated cirrhosis. *Cancer* 86: 589-595, 1999.
- 35 Lee JS, Chu IS, Mikaelyan A, Calvisi DF, Heo J, Reddy JK and Thorgeirsson SS: Application of comparative functional genomics to identify best-fit mouse models to study human cancer. *Nat Genet* 36: 1306-1311, 2004.

Received November 25, 2005

Revised February 1, 2006

Accepted February 9, 2006