

Review

Can Imatinib Be Safely Withdrawn in Patients with Surgically Resected Metastatic GIST?

IVAR HOMPLAND¹ and ØYVIND S. BRULAND^{1,2}

¹Department of Oncology, Oslo University Hospital, Norwegian Radium Hospital, Oslo, Norway;

²Institute of Clinical Medicine, University of Oslo, Oslo, Norway

Abstract. *Patients with advanced gastrointestinal stromal tumors (GIST) are currently recommended for treatment with tyrosine kinase inhibitors (TKI) in a life-long sequence. The standard first-line treatment is imatinib mesylate (IM), which is switched to other drugs at progression or if the patient does not tolerate IM. This strategy has served many patients well as patients with advanced GIST now live for a median of approximately 5 years, compared to 18 months prior the TKI era. The prevailing hypothesis is that IM and other TKIs fail to completely eradicate metastatic GIST and that progression is inevitable if IM treatment is discontinued. Following a response to IM and surgery of metastatic lesions harbouring foci responsible for drug resistance and subsequent clinical relapse, we hypothesize that this may lead to a cure and the justification to stop IM in selected patients. We suggest that this novel strategy, a priori, warrants further investigation. We reviewed the available literature, present three clinical cases and put forward for discussion a treatment algorithm that needs confirmation within the context of a prospective clinical study.*

Historically, patients with advanced gastrointestinal stromal tumors (GIST) had a very poor prognosis (1, 2). Treatment was mostly limited to surgery due to the poor response of GIST to conventional chemotherapy and radiotherapy (3). The detection of mutations in the *KIT* oncogene (4) led to the treatment paradigm of imatinib mesylate (IM) in GIST (5). This small

molecule, an inhibitor of tyrosine kinase receptors, including stem cell factor receptor *KIT* and the platelet-derived growth factor receptor- α (*PDGFRA*), blocks downstream signaling cascades in GIST cells, the main driver of tumor progression (4, 5). Imatinib revolutionized the treatment of patients with advanced GIST (6) and became the model of targeted-therapy in solid tumors; it is now considered to be the standard first-line medical treatment of GIST (7, 8). The median duration of response to IM in advanced GIST is 2-3 years with approximately 20% of the responses lasting for 10 or more years (3, 9). Most GISTs eventually progress on IM, which may then be replaced by other tyrosine kinase inhibitors (TKIs), such as sunitinib (second-line therapy) and regorafenib (third-line therapy) (7, 8). The frequently cited treatment guidelines recommend continuous and 'life-long' TKI administration for patients with advanced GIST (7, 8). This has served many patients well, as patients now live for a median of approximately 5 years after detection of metastatic disease, compared to 18 months prior the TKI era (9-11). Currently, a number of new TKIs, alone or in combination (*e.g.* NCT02365441), are being evaluated alongside treatment options alternative to inhibiting the *KIT* pathway. Although there has been a dramatic improvement in GIST outcomes, the prevailing hypothesis is that IM and other TKIs fail to completely eradicate the disease and that progression of metastatic GIST is inevitable if IM treatment is discontinued.

Case 1

A 52-year-old man had a complete resection of a 20-cm small bowel GIST with few mitoses in August 2002. In June 2005, the patient had IM initiated due to presence of one large and one small liver metastasis (Figure 1). The metastases were surgically excised in April 2008; they revealed pygnotic *KIT*-positive cells in hyaline stroma compatible with IM response. Tumor mutation analysis showed *KIT* exon 11 mutation del556-557. Imatinib was restarted after metastasectomy. The patient has had no

This article is freely accessible online.

Correspondence to: Prof. Øyvind S Bruland, MD, Ph.D., Institute of Clinical Medicine, University of Oslo and Norwegian Radium Hospital–Oslo University Hospital, Ullernchausseen 70, 0379 Oslo, Norway. Tel: +47 22934767, Fax: +47 22525559, e-mail: osb@ous-hf.no, oyvind.bruland@medisin.uio.no

Key Words: GIST, imatinib, surgery, discontinuation of treatment, cure, treatment algorithm, review.

evidence of relapse since metastasectomy, the last evaluation being in December 2014. Is it safe to discontinue imatinib after now almost 10 years on IM?

Case 2

A 67-year-old woman had a complete resection of a 9-cm small bowel GIST and five peritoneal lesions in July 2004. Histopathological examination revealed KIT-positive GIST with 13 mitoses per 50 high-power field (HPF). The peritoneal lesions were confirmed as GIST metastases. She was entered into the SSGXVIII/AIO trial (20) and was randomly assigned to the 1-year group. The IM dose of 400 mg/day was reduced to 300 mg/day due to neutropenia. Central pathology review confirmed the diagnosis of GIST. No mutation was found in sequencing of *KIT* and *PDGFRA* (*KIT* exon 17 and *PDGFRA* exon 12 yielded uninformative results), suggesting an uncommon tumor genetic make-up. Two peritoneal metastases were then detected by computerized tomography of the abdomen (Figure 2) 2 years after discontinuation of adjuvant IM. They were excised in April 2007, but IM was not restarted due to her history of poor tolerance. She has now been followed-up with repeated imaging for 8 years after metastasectomy with no signs of GIST recurrence.

Case 3

A 53-year-old man had a complete resection of a 15-cm stomach GIST in January 2010. Histopathological examination revealed KIT-positive GIST with nine mitoses per 50 HPF. Tumor mutation analysis showed *KIT* exon 11 mutation ins1754-1789. He received adjuvant IM for 1 year. A solitary liver metastasis was detected on a CT scan of the abdomen 6 months (February 2012) after the discontinuation of adjuvant IM (Figure 3), and IM was re-instituted. PET CT and dynamic MRI showed a remarkable response 1 month after the start of treatment. In June 2015, after 3 years of stable disease on IM, the small inactive liver metastasis was laparoscopically resected due to adverse events limiting his quality of life. In consultation with the patient, it was decided not to restart IM and perform careful follow-up instead.

Discontinuation of Imatinib

A significant body of evidence supports the current practice of administering IM until progression or indefinitely in the absence of progression. Only a small minority (0% to 5%) of patients with advanced GIST achieve complete response (CR) with IM, most responses being partial response (PR) or stable disease (SD) (12-14). In the BFR14 trial, patients with advanced GIST who were responding to first-line IM were randomly assigned either to continue IM or to stop it at the time of randomization (15-17). Almost all patients who stopped had GIST progression

within 2 years from the date of randomization, regardless of whether the patient had been on IM 1, 3, or 5 years prior to IM discontinuation. This led to a substantially shorter time to GIST progression in the stop group. Stopping IM did not, however, significantly influence overall survival (OS), likely since most patients in the group that stopped responded to IM reinstitution. Yet, the quality of the responses achieved after restarting IM were generally judged inferior compared to those achieved prior to IM discontinuation (16, 17).

Adjuvant Imatinib in Primary High-risk GIST

Individuals at intermediate or high risk of recurrence are now given adjuvant IM after surgery of a primary GIST (7, 8). Modified National Institutes of Health (NIH) criteria encompass four factors; size, mitotic count, site, and rupture, that are used to select patients for adjuvant treatment (18). A large adjuvant trial that compared 1 year of adjuvant IM to a placebo found that the recurrence-free survival (RFS) benefit achieved with adjuvant IM gradually faded over a long follow-up with no difference in OS between the two groups (19). This indicated that IM controls most GISTs but does not cure patients. The SSGXVIII/AIO trial, however, found that 3 years of adjuvant IM yielded both superior RFS and OS rates compared to 1 year of adjuvant IM (20). Three years of adjuvant IM is now recommended in the treatment guidelines (7, 8). Mature follow-up from the SSGXVIII/AIO trial showed that survival benefits persist (21), lending support to a hypothesis that sufficiently long administration of IM may sometimes eradicate sub-clinical GIST. The role of adjuvant IM has not yet been fully studied, and treatment duration of longer than 3 years may be needed to further reduce or even prevent recurrence. Currently, two trials (NCT02413736 and NCT00867113) are evaluating a duration longer than 3 years of adjuvant IM in GIST.

Imatinib: Toxicity and Side-effects

Imatinib is moderately- to well-tolerated, and several of the adverse effects can be ameliorated with supportive measures or dosing modifications (22). While severe adverse effects are infrequent, almost all treated patients have side-effects, the most frequent being anaemia, periorbital oedema, muscle cramps, and diarrhea (3, 6, 20). Compliance, *i.e.* adherence to self-administered IM, can be a challenge for patients on chronic therapy, as reported for patients with GIST who were taking IM long term (23). In the SSGXVIII/AIO trial, the proportion of patients who discontinued IM during the assigned treatment period not due to disease recurrence was 25.8% in the 36-month group compared to 12.6% in the 12-month group (20). This suggests that IM for some patients limits quality of life. At present, IM is costly both to individual patients and the health system.

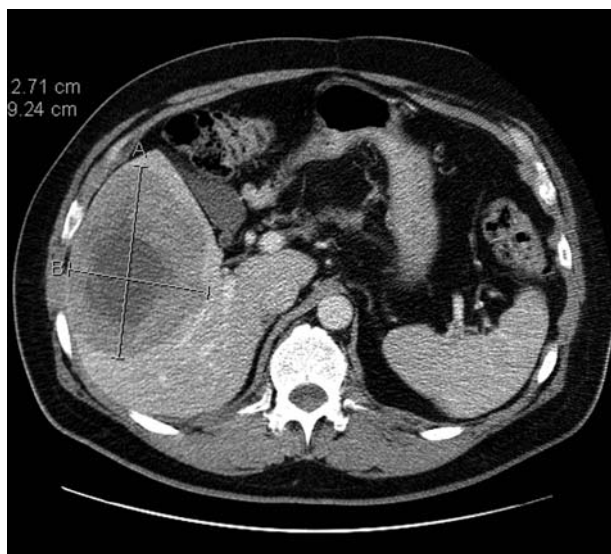


Figure 1. The larger liver metastasis detected on a CT scan before the start of IM in case 1.

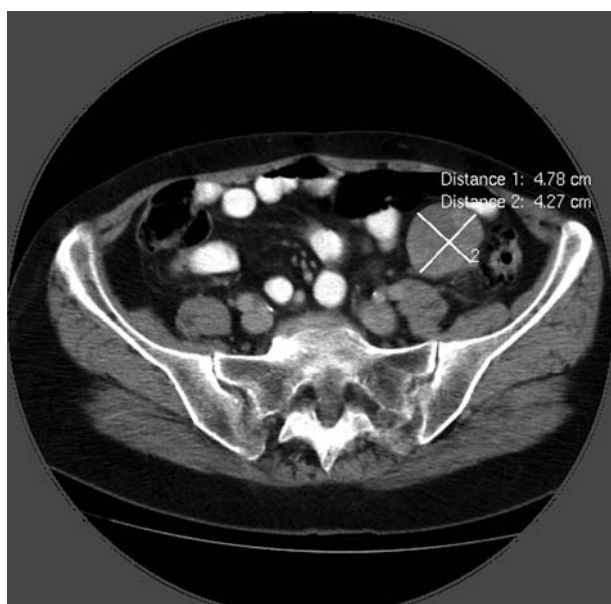


Figure 2. One of the two intraperitoneal metastases detected on a CT scan following adjuvant IM in case 2.

Metastasectomy: Removing a Reservoir of Dormant GIST cells

Metastasectomy may lead to long remission or even to cure in the treatment of some cancer types, including sarcoma (24-27). Approximately 30% of patients with soft tissue sarcoma or osteosarcoma who relapse with lung metastases and who undergo metastasectomy become long-term

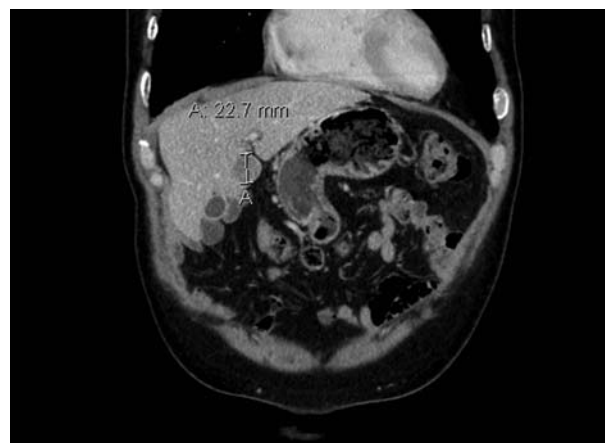


Figure 3. A small solitary liver metastasis detected on a CT scan in case 3.

survivors (24, 28, 29). Similarly, about 30% of selected colorectal cancer patients who have liver metastases resected survive for 5 years or longer after metastasectomy (30, 31). Historically, surgery for metastatic disease in the pre-IM era was universally associated with recurrence, and median survival was 15-20 months (1). In a study of 94 patients who presented with metastatic GIST, complete gross resection was possible in only 30% and the median survival of those treated with surgery alone was 19 months (2). As already mentioned, IM is not curative despite up to 80% of patients with metastatic GIST exhibiting some response or SD on the drug (12-14). This creates the opportunity for surgery to be combined with TKI therapy in order to improve outcomes. Several retrospective studies have reported favourable outcomes of surgery in metastatic GIST patients responding to IM (32-35); however, selection bias cannot be excluded. A large randomized trial that attempted to evaluate metastasis surgery was terminated due to poor accrual (NCT00956072). Hence, it remains unknown whether metastasectomy is beneficial or even harmful in the treatment of advanced GIST. A small prospective study randomized 41 patients with liver metastases from GIST to IM-alone *versus* IM followed by surgery and then additional IM (36). Patients were followed-up for 36 months and the 1- and 3-year survival rates were higher in the surgery group when compared to the IM-only group (100% and 89% vs. 85% and 60%, respectively). However, whether resection combined with TKI therapy truly confers a survival advantage still awaits a larger randomized controlled trial. Theoretically, surgery of residual disease can prolong durable remission because the excision of the tumor is performed before the development of IM resistance and thus the risk of subsequent disease progression. In the retrospective studies mentioned above, the patients who had metastasis surgery at the time of

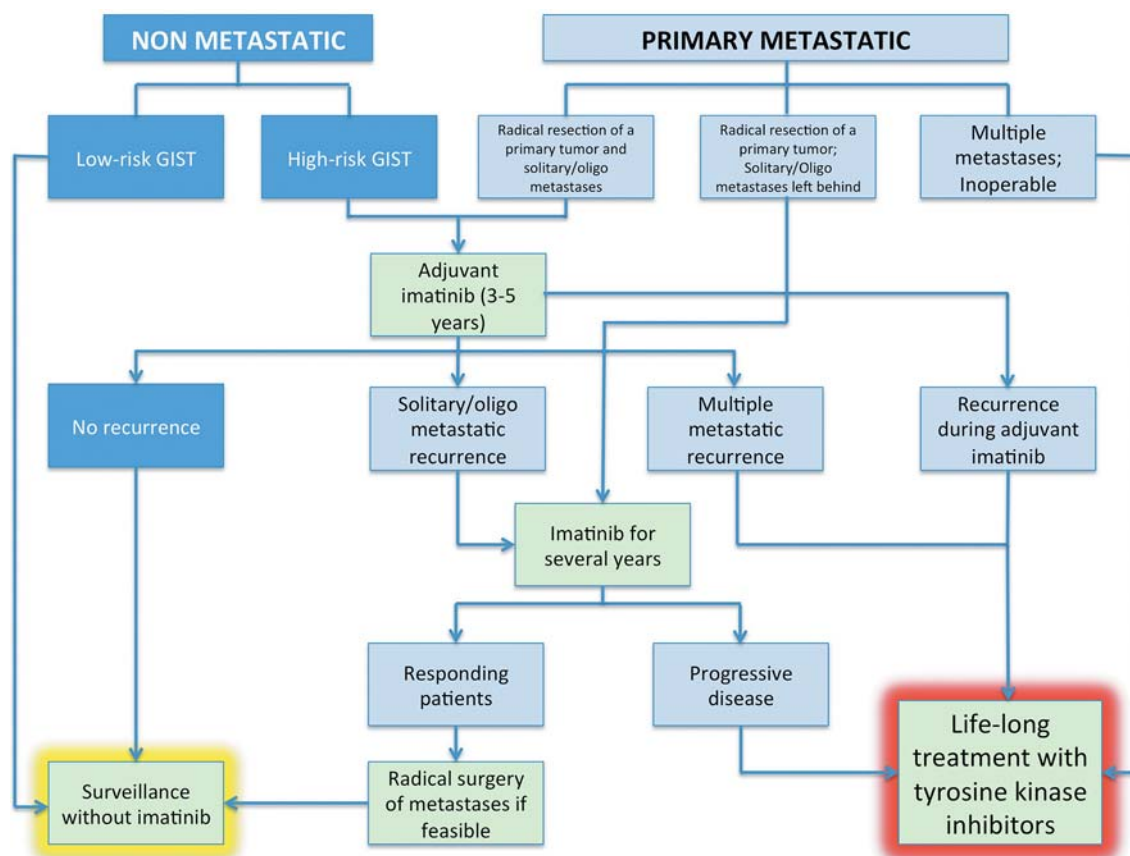


Figure 4. A novel treatment algorithm for GIST put forward for discussion. We emphasize that this treatment strategy should not be done in routine practice but preferentially explored in a prospective clinical trial. In the flowchart, non-metastatic GIST is shown in dark blue, metastatic GIST is in light blue, and suggested treatment recommendations are in green.

GIST progression did poorly compared to those who were operated on while still responding to TKI therapy (32, 33).

Imatinib: Both Cytotoxic and Cytostatic

It seems evident that IM does not eradicate overt macroscopic GIST metastases in the great majority of patients. Interestingly, IM is considered both a cytotoxic and a cytostatic drug. The cytotoxic effect is a well-described phenomenon, and evidence shows that tumor cells are replaced by myxoid degeneration after GIST patients have been treated with IM for as little as 4 weeks (5). Myxoid degeneration refers to the proteinaceous material left behind after cell death. This decrease in cellularity suggests that the GIST cells have undergone cell death. Moreover, there have been laboratory studies showing that IM induces apoptosis in GIST cells (37, 38). However, Liu and colleagues demonstrated that IM induces GIST tumour cell quiescence (withdrawal from the cell cycle) in cells that do not enter apoptosis (39). Also, dormant GIST cells are virtually always found in sizable metastases excised from responding

patients (19, 33), supporting a hypothesis that there is, despite a cytotoxic effect, also a cytostatic effect. This experience is shared with other TKIs (40). Interestingly, some patients with chronic myeloid leukaemia (CML) who have maintained durable complete molecular remission did not have rapid CML recurrence despite IM discontinuation, suggesting that some patients with CML might be cured with TKIs (41, 42). Dormant GIST cells may eventually develop IM resistance mutations over time, and since cells within the smallest GIST deposits might be eradicated with IM treatment, complete surgery of larger metastatic foci might, for some patients, potentially lead to cure. A possibility that complete metastasis surgery following durable IM treatment might sometimes lead to cure in GIST patients cannot be refuted. The patient in case 1 had his liver metastases resected, and has in total been on IM for almost 10 years without any signs of recurrence. In that case we have considered stopping IM as an option. The patient described in case 2 had no GIST progression during the 8 years that followed her second metastasectomy. Hence, the decision to refrain from IM served this patient well.

Safe discontinuation: Is it Feasible in Selected Patients Stable on Imatinib?

Can we safely stop IM in patients stable on IM? How should we select these patients? As mentioned above, following primary IM treatment in metastatic GIST patients, more than 80% of patients either respond to or achieve durable SD whereas less than 20% of patients progress (6, 9, 10). If patients relapse after adjuvant IM (1 to 3 years), the first choice of treatment is still IM, seemingly with the same response rate as for primary treatment with IM. In the SSGXVIII/AIO trial, 84% of patients who completed adjuvant IM and then received IM for recurrent GIST responded to IM re-introduction (43). This was independent of the length of prior IM therapy in the adjuvant setting (1 *versus* 3 years) (43). In the French BFR 14 trial mentioned above, stopping IM did not influence OS, and 96% of the patients responded to the reinstitution of IM (15-17). However, patients with PD following IM interruption were not always able to achieve the same degree of tumor control as they had before interrupting therapy (16). This might be of concern because tumor volume (the diameter of the largest metastases) seems to be a negative prognostic factor, both for PFS and OS (10, 44, 45). A concern is that a few patients in the BRF14 trial progressing rapidly after IM interruption had a poorer prognosis (46). Another issue regarding IM interruption is whether it may affect (positively or negatively) the incidence of secondary resistance to IM, which is most often caused by the acquisition of secondary KIT mutations (usually KIT Exon 13, 14, and 17) (47, 48). An analysis in the BFR14 trial compared the time to first progression in patients on continuous IM *versus* the time to second progression in patients after IM rechallenge. IM-resistant PFS was not significantly different between the continuation and the interruption groups for patients randomized to interruption at 1, 3, or 5 years (49). This might suggest a lack of effect on the IM-resistance selection process by treatment discontinuation. Taking all this into consideration, it seems compelling that it is possible to safely discontinue IM in patients with radically resected metastatic GIST without sacrificing too much for the individual patients. This presupposes that IM is restarted as soon as possible if a recurrence occurs. Strict monitoring with regular radiological imaging is then mandatory to detect any recurrence.

In Figure 4, we present a novel treatment algorithm for GIST put forward for discussion. This should, however, be considered with caution since a rapid progression after discontinuation, a poorer quality of volumetric response at IM re-challenge, and the growth of remaining persistent/resistant sub-clinical disease may impact the long-term outcome of patients. For all these reasons, treatment interruption should not be recommended outside clinical trials unless patients experience substantial toxic effects. In a

clinical scenario, such as case 3 (patient experiencing adverse effects limiting his daily activity), we have now decided to explore discontinuation of IM after surgical resection of a solitary liver metastasis. The patient is being carefully followed at the Norwegian Radium Hospital.

Conclusion

While continuous 'life-long' IM administration is and should be the standard-of-care for patients with advanced GIST, we propose an experimental treatment strategy in selected patients comprising of IM administration for a few years, metastasectomy, and close surveillance with repeat abdominal imaging after stopping IM. An optimal target group may be patients who, by imaging, have only one or few metastases that can likely be resected without major morbidity and with a documented response to IM. Frequent surveillance by proper imaging modalities to detect recurrence early is then critical. This treatment strategy should, however, not be performed in routine practice but preferentially in a prospective clinical trial or a multi-national registry. Even a single-group observational study would likely be informative.

Conflicts of Interest

The Authors have no conflicts of interest.

References

- 1 Gold JS, van der Zwan SM, Gönen M, Maki RG, Singer S, Brennan MF, Antonescu CR and DeMatteo RP: Outcome of Metastatic GIST in the Era before Tyrosine Kinase Inhibitors. *Ann Surg Oncol* 14: 134-142, 2006.
- 2 DeMatteo RP, Lewis JJ, Leung D, Mudan SS, Woodruff JM and Brennan MF: Two hundred gastrointestinal stromal tumors: recurrence patterns and prognostic factors for survival. *Ann Surg* 231: 51-58, 2000.
- 3 Joensuu H, Hohenberger P and Corless CL: Gastrointestinal stromal tumour. *The Lancet* 382: 973-983, 2013.
- 4 Hirota S, Isozaki K, Moriyama Y, Hashimoto K, Nishida T, Ishiguro S, Kawano K, Hanada M, Kurata A, Takeda M, Muhammad Tunio G, Matsuzawa Y, Kanakura Y, Shinomura Y and Kitamura Y: Gain-of-function mutations of c-kit in human gastrointestinal stromal tumors. *Science* 279: 577-580, 1998.
- 5 Joensuu H, Roberts PJ, Sarlomo-Rikala M, Andersson LC, Tervahartiala P, Tuveson D, Silberman S, Capdeville R, Dimitrijevic S, Druker B and Demetri GD: Effect of the tyrosine kinase inhibitor STI571 in a patient with a metastatic gastrointestinal stromal tumor. *N Engl J Med* 344: 1052-1056, 2001.
- 6 Demetri GD, von Mehren M, Blanke CD, Van den Abbeele AD, Eisenberg B, Roberts J, Heinrich MC, Tuveson DA, Singer S, Janicek M, Fletcher JA, Silverman SG, Silberman SL, Capdeville R, Kiese B, Peng B, Dimitrijevic S, Druker BJ, Corless C, Fletcher CD and Joensuu H: Efficacy and safety of imatinib mesylate in advanced gastrointestinal stromal tumors. *N Engl J Med* 347: 472-480, 2002.

- 7 ESMO/European Sarcoma Network Working Group: Gastrointestinal stromal tumours: ESMO Clinical Practice Guidelines for diagnosis, treatment and follow-up. *Ann Oncol* 25(Suppl 3): iii21-26, 2014.
- 8 National Comprehensive Cancer Network Guidelines Version 2.2014. http://www.nccn.org/professionals/physician_gls/pdf/sarcoma.pdf (accessed 6 June 2015).
- 9 Demetri GD, Rankin CJ and Benjamin RS: Long-term disease control of advanced gastrointestinal stromal tumors (GIST) with imatinib: 10-year outcomes from SWOG phase III intergroup trial S0033. *J Clin Oncol* 32: 5s (suppl; abstr 10508), 2014.
- 10 Blanke CD, Demetri GD, Mehren von M, Heinrich MC, Eisenberg B, Fletcher JA, Corless CL, Fletcher CDM, Roberts PJ, Heinz D, Wehre E, Nikolova Z and Joensuu H: Long-Term Results From a Randomized Phase II Trial of Standard- Versus Higher-Dose Imatinib Mesylate for Patients With Unresectable or Metastatic Gastrointestinal Stromal Tumors Expressing KIT. *J Clin Oncol* 26: 620-625, 2008.
- 11 Gastrointestinal Stromal Tumor Meta-Analysis Group (MetaGIST): Comparison of two doses of imatinib for the treatment of unresectable or metastatic gastrointestinal stromal tumors: a meta-analysis of 1,640 patients. *J Clin Oncol* 28: 1247-1253, 2010.
- 12 Demetri GD, Wang Y, Wehrle E, Racine A, Nikolova Z, Blanke CD, Joensuu H and Mehren von M: Imatinib plasma levels are correlated with clinical benefit in patients with unresectable/metastatic gastrointestinal stromal tumors. *J Clin Oncol* 27: 3141-3147, 2009.
- 13 Blanke CD, Rankin C, Demetri GD, Ryan CW, Mehren von M, Benjamin RS, Raymond AK, Bramwell VHC, Baker LH, Maki RG, Tanaka M, Hecht JR, Heinrich MC, Fletcher CDM, Crowley JJ and Borden EC: Phase III randomized, intergroup trial assessing imatinib mesylate at two dose levels in patients with unresectable or metastatic gastrointestinal stromal tumors expressing the kit receptor tyrosine kinase: S0033. *J Clin Oncol* 26: 626-632, 2008.
- 14 Verweij J, Casali PG, Zalcberg J, LeCesne A, Reichardt P, Blay J-Y, Issels R, van Oosterom A, Hogendoorn PC, van Glabbeke M, Bertulli R and Judson I: Progression-free survival in gastrointestinal stromal tumours with high-dose imatinib: randomised trial. *The Lancet* 364: 1127-1134, 2004.
- 15 Blay J-Y, Le Cesne A, Ray-Coquard I, Bui B, Duffaud F, Delbaldo C, Adenis A, Viens P, Rios M, Bompas E, Cupissol D, Guillemet C, Kerbrat P, Fayette J, Chabaud S, Berthaud P and Pérol D: Prospective multicentric randomized phase III study of imatinib in patients with advanced gastrointestinal stromal tumors comparing interruption *versus* continuation of treatment beyond 1 year: the French Sarcoma Group. *J Clin Oncol* 25: 1107-1113, 2007.
- 16 Le Cesne A, Ray-Coquard I, Bui BN, Adenis A, Rios M, Bertucci F, Duffaud F, Chevreau C, Cupissol D, Cioffi A, Emile J-F, Chabaud S, Pérol D, Blay J-Y and Group FTFS: Discontinuation of imatinib in patients with advanced gastrointestinal stromal tumours after 3 years of treatment: an open-label multicentre randomised phase 3 trial. *Lancet Oncology* 11: 942-949, 2010.
- 17 Blay JY, Perol D and Le Cesne A: Imatinib rechallenge in patients with advanced gastrointestinal stromal tumors. *Ann Oncol* 23: 1659-1665, 2012.
- 18 Joensuu H: Risk stratification of patients diagnosed with gastrointestinal stromal tumor. *Hum Pathol* 39: 1411-1419, 2008.
- 19 Corless CL, Ballman KV, Antonescu CR, Kolesnikova V, Maki RG, Pisters PWT, Blackstein ME, Blanke CD, Demetri GD, Heinrich MC, Mehren von M, Patel S, McCarter MD, Owzar K and DeMatteo RP: Pathologic and molecular features correlate with long-term outcome after adjuvant therapy of resected primary GI stromal tumor: the ACOSOG Z9001 trial. *J Clin Oncol* 32: 1563-1570, 2014.
- 20 Joensuu H, Eriksson M, Sundby Hall K, Hartmann JT, Pink D, Schütte J, Ramadori G, Hohenberger P, Duyster J, Al-Batran S-E, Schlemmer M, Bauer S, Wardelmann E, Sarlomo-Rikala M, Nilsson B, Sihto H, Monge OR, Bono P, Kallio R, Vehtari A, Leinonen M, Alvegård T and Reichardt P: One vs. three years of adjuvant imatinib for operable gastrointestinal stromal tumor: a randomized trial. *JAMA* 307: 1265-1272, 2012.
- 21 J Joensuu H, Eriksson M and Sundby Hall K *et al*: Three vs. 1 year of adjuvant imatinib (IM) for operable high-risk GIST: The second planned analysis of the randomized SSGXVIII/AIO trial. *J Clin Oncol* 33: (suppl; abstr 10505), 2015.
- 22 Joensuu H, Trent JC and Reichardt P: Practical management of tyrosine kinase inhibitor-associated side effects in GIST. *Cancer Treat Rev* 37: 75-88, 2011.
- 23 Mazzeo F, Duck L, Joosens E, Dirix L, Focan C, Forget F, De Geest S, Muermans K, van Lierde M-A, Macdonald K, Abraham I and De Grève J: Nonadherence to imatinib treatment in patients with gastrointestinal stromal tumors: the ADAGIO study. *Anticancer Res* 31: 1407-1409, 2011.
- 24 Billingsley KG, Burt ME, Jara E, Ginsberg RJ, Woodruff JM, Leung DH and Brennan MF: Pulmonary metastases from soft tissue sarcoma: analysis of patterns of diseases and postmetastasis survival. *Ann Surg* 229: 602-10- discussion 610-2, 1999.
- 25 Ohnstad HO, Bruland ØS, Taksdal I, Bjerkehagen B, Nenadovic M, Sæter G, Jørgensen LH and Hall KS: Response to preoperative chemotherapy in patients undergoing resection of pulmonary metastasis from soft tissue sarcoma – a predictor of outcome? *Acta Oncol* 53: 1180-1187, 2014.
- 26 Berner K, Hall KS, Monge OR, Weedon-Fekjær H, Zaikova O and Bruland OS: Prognostic Factors and Treatment Results of High-Grade Osteosarcoma in Norway: A Scope Beyond the “Classical” Patient. *Sarcoma*: 1-14, 2015.
- 27 Kager L, Zoubek A, Pötschger U, Kastner U, Flège S, Kempf-Bielack B, Branscheid D, Kotz R, Salzer-Kuntschik M, Winkelmann W, Jundt G, Kabisch H, Reichardt P, Jürgens H, Gadner H and Bielack SS: Primary metastatic osteosarcoma: presentation and outcome of patients treated on neoadjuvant Cooperative Osteosarcoma Study Group protocols. *J Clin Oncol* 21: 2011-2018, 2003.
- 28 Hawkins DS and Arndt CAS: Pattern of disease recurrence and prognostic factors in patients with osteosarcoma treated with contemporary chemotherapy. *Cancer* 98: 2447-2456, 2003.
- 29 Daw NC, Chou AJ, Jaffe N, Rao BN, Billups CA, Rodriguez-Galindo C, Meyers PA and Huh WW: Recurrent osteosarcoma with a single pulmonary metastasis: a multi-institutional review. *Br J Cancer* 112: 278-282, 2014.
- 30 Simmonds PC, Primrose JN, Colquitt JL, Garden OJ, Poston GJ and Rees M: Surgical resection of hepatic metastases from colorectal cancer: A systematic review of published studies. *Br J Cancer* 94: 982-999, 2006.
- 31 Adams RB, Aloia TA, Loyer E, Pawlik TM, Taouli B and Vauthey J-N: Selection for hepatic resection of colorectal liver metastases: expert consensus statement. *HPB* 15: 91-103, 2013.

- 32 Raut CP, Posner M, Desai J, Morgan JA, George S, Zahrieh D, Fletcher CDM, Demetri GD and Bertagnoli MM: Surgical management of advanced gastrointestinal stromal tumors after treatment with targeted systemic therapy using kinase inhibitors. *J Clin Oncol* 24: 2325-2331, 2006.
- 33 Gronchi A, Fiore M, Miselli F, Lagonigro MS, Coco P, Messina A, Pilotti S and Casali PG: Surgery of residual disease following molecular-targeted therapy with imatinib mesylate in advanced/metastatic GIST. *Ann Surg* 245: 341-346, 2007.
- 34 Gronchi A and Raut CP: The combination of surgery and imatinib in GIST: A reality for localized tumors at high risk, an open issue for metastatic ones. *Ann Surg Oncol* 19: 1051-1055, 2011.
- 35 Tielen R, Verhoef C, van Coevorden F, Gelderblom H, Sleijfer S, Hartgrink HH, Bonenkamp JJ, van der Graaf WTA and de Wilt JHW: Surgical treatment of locally advanced, non-metastatic, gastrointestinal stromal tumours after treatment with imatinib. *European Journal of Surgical Oncology* 39: 150-155, 2013.
- 36 Xia L, Zhang M-M, Ji L, Li X and Wu X-T: Resection combined with imatinib therapy for liver metastases of gastrointestinal stromal tumors. *Surg Today* 40: 936-942, 2010.
- 37 Tuveson DA, Willis NA, Jacks T, Griffin JD, Singer S, Fletcher CD, Fletcher JA and Demetri GD: STI571 inactivation of the gastrointestinal stromal tumor c-KIT oncoprotein: biological and clinical implications. *Oncogene* 20: 5054-5058, 2001.
- 38 Boichuk S, Parry JA, Makielski KR, Litovchick L, Baron JL, Zewe JP, Woźniak A, Mehalek KR, Korzeniewski N, Seneviratne DS, Schöffski P, Dębiec-Rychter M, DeCaprio JA and Duensing A: The DREAM complex mediates GIST cell quiescence and is a novel therapeutic target to enhance imatinib-induced apoptosis. *Cancer Res* 73: 5120-5129, 2013.
- 39 Liu Y, Perdreau SA, Chatterjee P, Wang L, Kuan S-F and Duensing A: Imatinib mesylate induces quiescence in gastrointestinal stromal tumor cells through the CDH1-SKP2-p27Kip1 signaling axis. *Cancer Res* 68: 9015-9023, 2008.
- 40 Rixe O and Fojo T: Is cell death a critical end point for anticancer therapies or is cytostasis sufficient? *Clin Cancer Res* 13: 7280-7287, 2007.
- 41 Mahon F-X, Réa D, Guilhot J, Guilhot F, Huguot F, Nicolini F, Legros L, Charbonnier A, Guerci A, Varet B, Etienne G, Reiffers J and Rousselot P: Discontinuation of imatinib in patients with chronic myeloid leukaemia who have maintained complete molecular remission for at least 2 years: the prospective, multicentre Stop Imatinib (STIM) trial. *Lancet Oncol* 11: 1029-1035, 2010.
- 42 Benjamini O, Kantarjian H, Rios MB, Jabbour E, O'Brien S, Jain P, Cardenas-Turan M, Faderl S, Garcia-Manero G, Ravandi F, Borthakur G, Quintas-Cardama A and Cortes J: Patient-driven discontinuation of tyrosine kinase inhibitors: single institution experience. *Leuk Lymphoma* 55: 2879-2886, 2014.
- 43 P Reichardt, JT Hartmann, K Sundby Hall *et al*: Response to imatinib rechallenge of GIST that recurs following completion of adjuvant imatinib treatment: the first analysis in the SSGXVIII/AIO trial patient population. *Eur J Cancer* 47(suppl 2): 15, 2015.
- 44 Rutkowski P, Andrzejuk J, Bylina E, Osuch C, Świtaj T, Jerzak vel Dobosz A, Grzesiakowska U, Jurkowska M, Woźniak A, Limon J, Dębiec-Rychter M and Siedlecki JA: What are the current outcomes of advanced gastrointestinal stromal tumors: who are the long-term survivors treated initially with imatinib? *Med Oncol* 30: 765-11, 2013.
- 45 Lee CK, Goldstein D, Gibbs E, Joensuu H, Zalcberg J, Verweij J, Casali PG, Maki RG, Cioffi A, Mcarthur G, Lord SJ, Yip D, Kanjanapan Y and Rutkowski P: Development and validation of prognostic nomograms for metastatic gastrointestinal stromal tumour treated with imatinib. *Eur J Cancer* 51: 852-860, 2015.
- 46 Patrikidou A, Chabaud S, Ray-Coquard I, Bui BN, Adenis A, Rios M, Bertucci F, Duffaud F, Chevreau C, Cupissol D, Domont J, Perol D, Blay JY, Le Cesne A French Sarcoma Group: Influence of imatinib interruption and rechallenge on the residual disease in patients with advanced GIST: results of the BFR14 prospective French Sarcoma Group randomised, phase III trial. *Ann Oncol* 24: 1087-1093, 2013.
- 47 Wardelmann E, Merkelbach-Bruse S, Pauls K, Thomas N, Schildhaus H-U, Heinicke T, Speidel N, Pietsch T, Buettner R, Pink D, Reichardt P and Hohenberger P: Polyclonal evolution of multiple secondary KIT mutations in gastrointestinal stromal tumors under treatment with imatinib mesylate. *Clin Cancer Res* 12: 1743-1749, 2006.
- 48 Heinrich MC, Corless CL, Blanke CD, Demetri GD, Joensuu H, Roberts PJ, Eisenberg BL, Mehren von M, Fletcher CDM, Sandau K, McDougall K, Ou W-B, Chen C-J and Fletcher JA: Molecular correlates of imatinib resistance in gastrointestinal stromal tumors. *J Clin Oncol* 24: 4764-4774, 2006.
- 49 Le Cesne A, Ray-Coquard IL, Bui Nguyen B *et al*: Time to secondary resistance (TSR) after interruption of imatinib (IM) in advanced GIST: updated results of the prospective French Sarcoma Group randomized phase III trial on long-term survival. *J Clin Oncol* 2011; 29: (suppl; abstr 10015).

Received July 20, 2015

Revised September 3, 2015

Accepted September 4, 2015