

Expression and Distribution of Tenascin in Rat Submandibular Glands Following Irradiation

S. BARTEL-FRIEDRICH¹, C. LAUTENSCHLÄGER², H.-J. HOLZHAUSEN³ and R.E. FRIEDRICH⁴

¹Department of Otorhinolaryngology, Section of Phoniatrics and Pedaudiology,

²Institute of Medical Biometry and Informatics, and

³Institute of Pathology, University Hospital, Martin Luther University Halle-Wittenberg, Germany;

⁴Department of Maxillofacial Surgery, Eppendorf University Hospital, Hamburg, Germany

Abstract. *The aim of this study was to investigate the late changes in the expression of tenascin-C (TN-C) in salivary glands (SG) following irradiation (IRR). Materials and Methods: In 124 submandibular SG from 62 Wistar rats, the effect of IRR dose (fractionated IRR, 2 Gy per day, total dose of 20, 40, or 60 Gy), time since IRR (6 months vs. 12 months), and animal age (1 year vs. 1.5 years) on TN-C expression profile and its distribution pattern was investigated. Results: Expression of TN-C showed slight to moderate alterations in the irradiated specimens. The expression differed in frequency and degree among various tissue structures. The most striking finding was pronounced dose-dependent heterogeneity, with increases, decreases and fluctuations in staining. Conclusion: The staining of TN-C predominantly showed notable dose-dependent heterogeneity, persisting for up to 1 year after completion of IRR. Thus, these findings can be attributed to late radiation effects. The altered expression of tenascin-C may play at least a partial role in late radiogenic dysfunction of the submandibular SG.*

Radiotherapy is often employed in the treatment of malignant tumours of the head and neck. Frequently, this causes salivary gland dysfunction with permanent xerostomia and impairments of swallowing, taste, and speech (1). The morphological pattern of radiogenic salivary gland damage demonstrates direct cell alterations, increasing parenchymal atrophy and increasing interstitial

fibrosis (1), which indicates direct cell damage (*e.g.* cell membrane injury and interphase cell death (2), DNA damage and mitotic cell death (3)) and mesenchymal or extracellular matrix (ECM) alterations (*e.g.* accelerated terminal differentiation of fibroblasts, elevated collagen deposits (4)) as the effects of radiation. Previous studies (5-7) supported the alterations in the ECM and showed an increasing and extended expression of various ECM proteins (EMP) including basement membrane alterations, following fractionated irradiation with total dosages up to 60 Gray (Gy) (5, 8, 9).

Within the ECM, tenascins form an intriguing protein family, with each member displaying distinct features (10). The first tenascin to be described, tenascin-C (TN-C), is a potentially useful marker for tissue remodeling due to its limited distribution in healthy individuals and in mature tissues (10, 11). The expression of TN-C is highly regulated both during development and in adults. TN-C is often transiently expressed during organogenesis, but it is absent or much reduced in most fully developed organs. However, TN-C is expressed at variable levels and in remodeled form under pathological conditions such as mammary gland involution, wound healing, infection, inflammation and tumourigenesis (10, 12-19). In addition, TN-C expression has been investigated following surgical intervention, radiotherapy and laser exposure (11, 20-24).

TN-C thus serves as an indicator of tissue restructuring and developing fibrosis, including radiofibrosis in tissues unaffected by cancer (11). Late radiation reactions are of particular clinical relevance. To date, TN-C changes in the parotid and lachrymal glands in the early phase (up to one month) after irradiation have been reported predominantly for protocols using single-shot or oligo-fractionated irradiation (25-28). Therefore, the aim of this study was to increase knowledge on TN-C expression in the late post-irradiation period following a clinically relevant irradiation protocol in submandibular gland tissues.

Correspondence to: Sylva Bartel-Friedrich, MD, Ph.D., Section of Phoniatrics and Pedaudiology, Department of Otorhinolaryngology, Head and Neck Surgery, University Hospital, Martin Luther University Halle-Wittenberg, Magdeburger Strasse 12, D-06097 Halle (Saale), Germany. Tel: +49 3455571784, Fax: +49 345557 1859, e-mail: sylva.bartel-friedrich@medizin.uni-halle.de

Key Words: Irradiation, damage, salivary glands, tenascin-C.

Table I. Age, radiation dose, and time since irradiation of the animals (N=62 investigated; N1=61 evaluated; n=122 left- and right sided glands).

	Group	Left-sided glands (in radiation field)	Right-sided glands (outside radiation field)	n
Age (years)	1	28	28	56
	1½	33	33	66
Irradiation (total x-ray dose, Gy)	0	10	10	20
	20	16	15	31
	40	18	18	36
	60	17	18	35
Time after irradiation	6 months	23	23	46
	12 months	28	28	56

Materials and Methods

All experiments were conducted in accordance with German law on protection of animals. The experiments were approved by the Ethics Committee of the University of Hamburg. In 124 submandibular gland specimens from 62 Wistar rats, the effect of irradiation dose (fractionated irradiation, 2 Gy per day, total dose of 20, 40, or 60 Gy), time since irradiation (6 months vs. 12 months) and animal age (1 year vs. 1.5 years; Table I) on TN-C expression profile and its distribution pattern were investigated. Details of immunohistochemical methods were as follows: antibody/source: monoclonal tenascin-TN2, diluted 1:50/Novocastra Laboratories Ltd, Newcastle upon Tyne, UK; visualisation of the antigen-antibody reaction: Chem Mater™ kit detection system, peroxidase, DAB. Semiquantitative assessment involved scoring of staining intensity according to the following scale: 1, negative; 2, trace; 3, slight; 4, moderate; 5, strong or very strong. Multivariate analysis was performed using the Statistical Package for Social Sciences (SPSS, version 15 for windows, obtained from SPSS Inc., Chicago, USA). The procedures for irradiation, anaesthesia for neck and skull base irradiation, and follow-up are described elsewhere in detail (5).

Results

TN-C expression was noted in the control glands as well as in the irradiated specimens. However, immunostaining differed in terms of distribution pattern and staining intensity between control and irradiated glands.

In non-irradiated animals (Figures 1 and 2), TN-C was detected at trace to slight levels around glandular tissue structures, including acinar cells (ACI), intercalated duct cells (ICD, in part showing laminar condensations), granular convoluted tubules (GCT), striated duct cells (SD), and excretory duct cells (ECD). Immunostaining was also observed in vascular walls (with marked staining in the adventitia) and in nerve tissue (epineurial fibroblasts and Schwann cells). An intracellular parenchymal expression at trace level was restricted to ACI and myoepithelial cells

(MYO). No reaction was found in the capsule and the trabeculae or stromal mesenchymal cells (e.g. fibroblasts), respectively.

In irradiated animals (Figures 3 and 4), expression of TN-C showed slight to moderate alterations depending on irradiation or dose and sometimes latency period or age. The expression differed in frequency and degree among the various tissue structures. The most striking finding was pronounced dose-dependent heterogeneity, with increases, decreases and fluctuations in staining.

In ACI, the largely periacinar immune reaction in control glands decreased in irradiated glands ($p \leq 0.05$), while intracellular staining increased (controls vs. 20/40/60 Gy: $p = 0.02/0.04/0.02$, respectively). Furthermore, the intracellular ACI staining of shielded right-sided glands was intensified ($p \leq 0.05$), but the effect decreased with increasing dose, so that the two sides of irradiated animals showed different staining ($p = 0.01$).

The TN-C expression surrounding ICD in irradiated glands was significantly lower than in controls (controls vs. 20/40/60 Gy: $p \leq 0.05/0.03/0.01$, respectively), especially 6 months following irradiation (6- vs. 12- month latency: $p \leq 0.001$). In contrast to control glands, the ICD of irradiated glands displayed an intracellular dose-independent staining at trace to slight levels (controls vs. 20/40/60 Gy: $p = 0.01/<0.001/<0.001$, respectively). Although there was also a slight intracellular immune reaction in shielded right-sided glands of irradiated animals, the two sides differed significantly in their expression profile ($p = 0.04$).

The TN-C expression surrounding SD in irradiated glands revealed an increasing reaction following 20 and 60 Gy exposure, but a distinct decrease in expression at 40 Gy ($p = 0.004$). Staining increased with increasing latency period (6- vs. 12-month latency: $p \leq 0.01$). Some SD showed an intracellular staining at low level (not significant comparing to controls).

TN-C expression around ECD in directly exposed glands displayed an increasing reaction following 20 and 60 Gy exposure, but a distinct decrease at 40 Gy ($p=0.04$). Staining increased with increasing latency period (6- vs. 12-month latency: $p\leq 0.001$). Although the two sides of irradiated animals showed different expression levels ($p=0.004$), staining profile was similar ($p=0.3$). Although the difference from controls was not significant, some ECD showed low-level intracellular staining.

In vascular walls the expression in the adventitia increased in both the directly exposed glands and the shielded right-sided glands of irradiated animals (controls vs. 20/40/60 Gy: $p\leq 0.001/0.001/0.001$, respectively), while the endothelial tissue layer and the tunica media showed no differences in immunostaining. In addition, no significant differences in expression were detected in GCT, capsule or trabeculae. Some irradiated glands showed TN-C expression in stromal fibroblasts and a slight fibrillar staining pattern in the mesenchymal tissue surrounding TN-C-positive infiltrative cells.

In MYO, there was a tendency towards increased TN-C expression in irradiated glands ($p=0.06$), especially 6 months following irradiation (controls vs. 6-month latency: $p=0.06$).

In nerve tissues, the TN-C immune reaction of the Schwann cells increased in irradiated specimens ($p=0.001$), especially when comparing glands exposed to 40 Gy and 60 Gy ($p=0.003$). Other cellular structures in the inner parts of the nerve endings, such as perineurial and endoneurial fibroblasts, were not detected. The epineurial expression in fibroblasts of directly exposed glands tended towards increasing expression up to 40 Gy ($p=0.05$) and with increasing age, but revealed a decreasing tendency at 60 Gy ($p=0.05$). However, in older animals, the shielded right-sided glands of irradiated animals showed a marked decrease in epineurial expression, reflecting age-dependent differences ($p=0.004$).

Discussion

Radiation-induced damage of the salivary glands following radiotherapy of the head and neck region is a well-known phenomenon (1). The extent of functional and morphological salivary tissue damage depends on the radiation dose, the fractionation scheme, the localisation in the radiation field and the time elapsed since completion of irradiation (1, 29, 30). In general, animal studies also show dose- and time-dependent effects of irradiation on salivary gland damage. The histological pattern of this damage demonstrates direct cell alterations, increasing parenchymal atrophy and increasing interstitial fibrosis, reflecting a remodeled and disordered tissue unit. In the search for specific morphological marker for lesions of radiation-induced injury, there has been an interest in the behavior of the ECM

glycoprotein TN-C, which serves as an indicator of tissue restructuring and remodeling (10) and developing fibrosis, including radiofibrosis in tissues unaffected by cancer (11). In recent animal studies, TN-C alterations in parotid and lachrymal gland tissues have been reported in the early phase (up to one month) after irradiation, predominantly for protocols using single-shot or oligo-fractionated irradiation (25-28). These studies demonstrated an up-regulation and marked redistribution of TN-C expression as early as 24 h after radiation (25) and a largely normal expression at 1 month post radiation (28). However, knowledge of the clinically important late radiogenic alterations of TN-C behavior is sparse.

The results of this study showed that in control glands, TN-C was expressed around nerve endings, blood vessels and the parenchymal structures adjacent to the basement membranes. Although somewhat more gland structures were stained, these results were in general agreement with the findings of Hakim *et al.* (25), Shrestha *et al.* (16) and Sunardhi-Widyaputra and Van Damme (15). In irradiated glands, a marked heterogeneity was observed, with increases, decreases and fluctuations in staining. In contrast to the findings of Hakim *et al.* (25), this heterogeneity showed dose-dependency and was sometimes also latency dependent. This heterogeneity can be interpreted as a result of using a clinically relevant therapeutic radiation protocol and of evaluating later post-irradiation periods. Previous studies evaluating cytokeratins and vimentin in rat larynx following irradiation (31) support this interpretation. Besides very early alterations, late alterations in TN-C expression have to also be taken into account in radiogenic salivary gland damage. Moreover, and in concordance with Hakim *et al.* (25), enhanced intracellular expression of TN-C in ACI and a tendency towards increase in MYO were observed, supporting the radiation-induced redistribution of TN-C and the theory of acinar cell or acinar cell membrane damage persisting into later postirradiation periods.

In later radiogenic salivary gland tissue changes, increased ECM protein content, *e.g.* enlarged collagen or fibronectin deposits resulting in increased connective tissue scar formation (1, 8, 9), has been described, together with altered expression of basement membranes, which are special structures of the ECM, resulting in disturbed cell-matrix interactions (5, 7). Myofibroblasts or fibroblasts, known as a source of TN-C in early radiogenic changes (25), are involved in later scar formation. In addition, a binding of TN-C to fibronectin (FN) and a co-localization of TN-C and FN in cell culture, in embryos (32) and in oral squamous cell carcinomas (33) have been reported. Thus, one could expect TN-C-positive stromal cells, as well as an elevated extracellular space expression in the connective tissue areas. However, these expectations were not corroborated in the present study. Only some

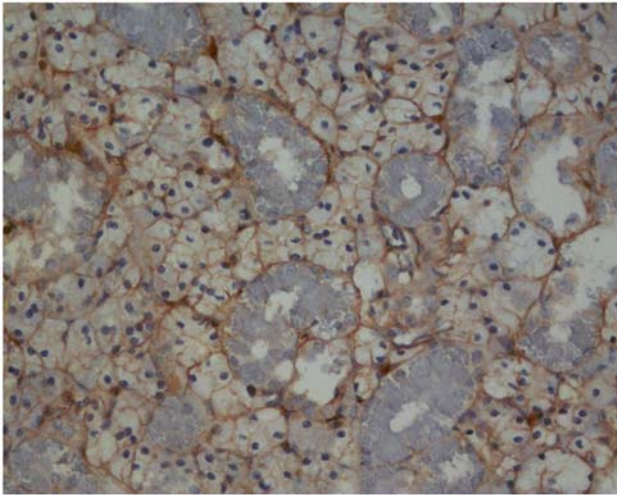


Figure 1. Rat mandibular gland, non-irradiated animal (control group), magnification $\times 200$. Band-like TN-C expression exists around glandular tissue structures adjacent to basement membranes. There is trace intracellular staining of ACI along with immune reactions of the basolateral cell borders. In part, laminar condensations are visible in the area of ICD.

irradiated glands showed TN-C expressions in stromal fibroblasts and slight fibrillar staining in the mesenchymal tissue surrounding TN-C-positive infiltrative cells. Regarding connective tissues in trabeculae and septa, the nearly completed changes in TN-C regulation or expression in glands evaluated 6 or 12 months after completion of irradiation may provide a possible explanation. However, the general question of whether impairment of the MYO or/and alteration of the corresponding MYO/sub-basement membrane transition region induces altered TN-C expression remains open. Nevertheless, the altered, albeit heterogeneous, TN-C expression adjacent to the basement membranes could support the theory that the cell-ECM transition zone may represent a target region influencing both salivary function (*e.g.* salivary secretion) and ECM expression in later post-irradiation periods.

As described in a previous study (5), a partially similar irradiation-dependent expression profile of a few tissue structures (ECD, vascular walls) was observed in directly exposed and shielded glands. Also in the present study, a scattered radiation effect was considered as a possible explanation.

In addition, as previously described by Hakim *et al.* (25) for the early postirradiation phase, the increased TN-C immune reaction of Schwann cells along with the marked tendency towards dose-dependent fluctuations in TN-C expression in epineurial fibroblasts could point to nerve tissue injury at the neuromotor level extending to late radiogenic reactions.

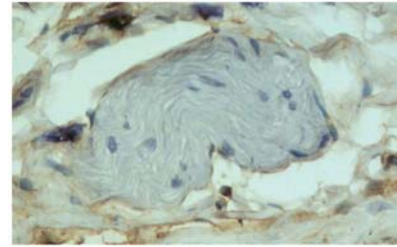


Figure 2. Rat mandibular gland, non-irradiated animal (control group), magnification $\times 200$. Nerve tissue showing trace to slight TN-C immunostaining in the epineurial region without expression of Schwann cells.

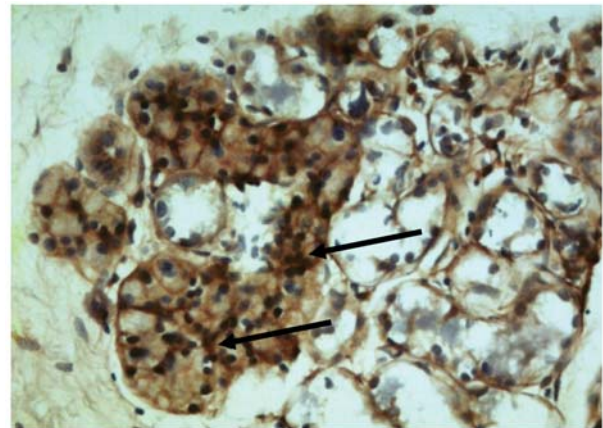


Figure 3. Rat mandibular gland, irradiated animal (dose 60 Gy), magnification $\times 200$. Intracellular TN-C staining of the ACI was distinctly stronger than in controls. In addition, the ICD showed intracellular expression (arrows).

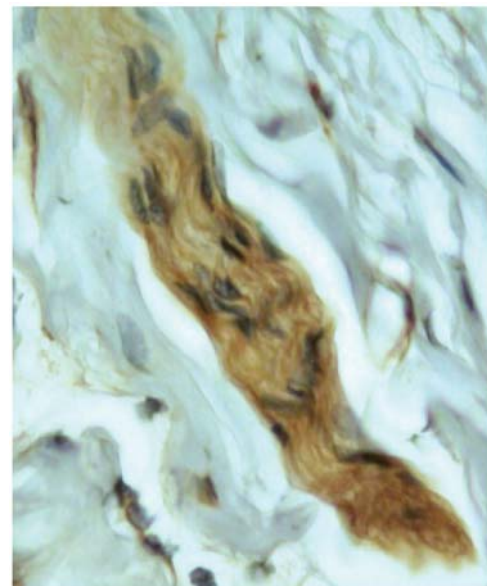


Figure 4. Rat mandibular gland, irradiated animal (dose 60 Gy), magnification $\times 400$. In the inner regions of nerve tissues, there was marked TN-C immunostaining of Schwann cells, while the epineurial parts showed trace expression.

Conclusion

The expression of tenascin-C predominantly showed notable dose-dependent heterogeneity, with increases, decreases and fluctuations in expression. The expression pattern persisted for up to 1 year after completion of irradiation. Thus, these findings can be attributed to late radiation effects. The altered expression of tenascin-C may play at least a partial role in late radiogenic dysfunction of the submandibular gland.

Acknowledgements

This study was generously supported by the Hamburger Stiftung zur Förderung der Krebsbekämpfung (project No. 149) and in part by the Deutsche Forschungsgemeinschaft (project no. FR 1035/1-2).

References

- Seifert G: *In: Oralpathologie I. Pathologie der Speicheldrüsen.* Doerr W and Seifert G (eds.). Berlin: Springer Verlag, 1996.
- Stephens LC, Ang KK, Schultheiss TE, King GK, Brock WA and Peters LJ: Target cell and mode of radiation injury in rhesus salivary glands. *Radiother Oncol* 7: 165-174, 1986.
- Herrmann T and Baumann M: Strahlenwirkung auf Normalgewebe. *In: Klinische Strahlenbiologie.* Herrmann Th and Baumann M (eds.). Jena: Gustav Fischer Verlag, pp. 80-109, 1997.
- Rodemann HP, Binder A and Bamberg M: Radiation-induced fibrosis: experimental studies. *In: Late sequelae in oncology.* Dunst J and Sauer R (eds.). Berlin: Springer Verlag, pp. 93-97, 1995.
- Bartel-Friedrich S, Friedrich RE, Lautenschläger C and Holzhausen HJ: Dose-response relationships and the effect of age and latency on the expression profile of laminin in irradiated rat mandibular glands. *Anticancer Res* 20: 5221-5228, 2000.
- Friedrich RE, Bartel-Friedrich S, Lautenschläger C and Holzhausen HJ: The effect of external fractionated irradiation on the distribution pattern of extracellular matrix proteins in submandibular salivary glands of the rat. *J Graniomaxillofac Surg* 30: 246-254, 2002.
- Gustafsson H, Aalto Y, Franzen L, Thornell LE and Hendriksson R: Effects of fractionated irradiation on the cytoskeleton and basal lamina in parotid glands – an immunohistochemical study. *Acta Oncol* 37: 33-40, 1998.
- Bartel-Friedrich S, Friedrich RE, Moll R and Lautenschläger C: Extracellular matrix proteins in the irradiated mandibular gland in rats. *Anticancer Res* 19: 2779-2784, 1999.
- Friedrich RE, Bartel-Friedrich S, Röser K and Lautenschläger C: The expression pattern of collagen I in irradiated mandibular salivary glands of rats. *Anticancer Res* 23: 927-930, 2003.
- Chiquet-Ehrismann R and Chiquet M: Tenascins: regulation and putative functions during pathological stress. *J Pathol* 200: 488-499, 2003.
- Wehrhan F, Rödel F, Grabenbauer G, Amann K, Brückl W and Schultze-Mosgau S: Transforming growth factor beta 1 dependent regulation of tenascin-C in radiation impaired wound healing. *Radiother Oncol* 72: 297-303, 2004.
- Inaguma YF, Kusakabe MF, Mackie EJ, Pearson CA, Chiquet-Ehrismann R and Sakakura T: Epithelial induction of stromal tenascin in the mouse mammary gland: from embryogenesis to carcinogenesis. *Dev Biol* 128: 245-255, 1988.
- Whitby DJ, Longaker MT, Harrison MR, Adzick NS and Ferguson MW: Rapid epithelialisation of fetal wounds is associated with the early deposition of tenascin. *J Cell Sci* 99: 583-586, 1991.
- Talhok RS, Bissell MJ and Werb Z: Coordinated expression of extracellular matrix-degrading proteinases and their inhibitors regulates mammary epithelial function during involution. *J Cell Biol* 118: 1271-1282, 1992.
- Sunardhi-Widyaputra S and Van Damme B: Immunohistochemical expression of tenascin in normal human salivary glands and in pleomorphic adenomas. *Pathol Res Pract* 189: 138-143, 1993.
- Shrestha P, Sumitomo SF, Ogata KF, Yamada KF, Takai YF, Yang LF and Mori M: Immunoreactive tenascin in tumours of salivary glands: evidence for enhanced expression in tumour stroma and production by tumour cells. *Eur J Cancer B Oral Oncol* 30B: 393-399, 1994.
- Chiquet-Ehrismann R: Tenascins, a growing family of extracellular matrix proteins. *Experientia* 51: 853-862, 1995.
- Shintani SF, Alcalde REF, Matsumura TF and Terakado N: Extracellular matrices expression in invasion area of adenoid cystic carcinoma of salivary glands. *Cancer Lett* 116: 9-14, 1997.
- Jones PL and Jones FS: Tenascin-C in development and disease: gene regulation and cell function. *Matrix Biol* 19: 581-596, 2000.
- Riekkilä R, Jukkola A, Oikarinen A and Kallioinen M: Radiation therapy induces tenascin expression and angiogenesis in human skin. *Acta Derm Venereol* 81: 329-333, 2001.
- Heimann H, Coupland SE, Gochman R, Hellmich M and Foerster MH: Alterations in expression of mucin, tenascin-c and syndecan-1 in the conjunctiva following retinal surgery and plaque radiotherapy. *Graefes Arch Clin Exp Ophthalmol* 239: 488-495, 2001.
- Gansera B, Rohrbach H, Gillrath G, Vogel V, Angelis I, Kiask T, Neumaier-Prauser P, Nerlich A and Kemkes BM: Is there a difference between diabetic and non-diabetic ITAs? Histomorphological and immunohistochemical examinations of internal thoracic arteries. *Thorac Cardiovasc Surg* 52: 255-260, 2004.
- Ferreira AN, Silveira L, Genovese WJ, de Araujo VC, Frigo L, de Mesquita RA and Guedes E: Effect of GaAIs laser on reactionary dentinogenesis induction in human teeth. *Photomed Laser Surg* 24: 358-365, 2006.
- Pfander D, Jorgensen B, Rohde E, Bindig U, Muller G and Scheller E: The influence of laser irradiation of low-power density on an experimental cartilage damage in rabbit knee-joints: an *in vivo* investigation considering macroscopic, histological and immunohistochemical changes. *Biomed Tech (Berl)* 51: 131-138. Erratum in: *Biomed Tech (Berl)* 51: 377-378, 2006.
- Hakim SG, Lauer I, Nadrowitz R, Berndt A, Kosmehl H and Sieg P: Re-distribution of tenascin-C in the parotid acinar cells. An early marker of radiation-induced damage of salivary glands? *Anticancer Res* 24: 2841-2846, 2004.
- Hakim SG, Kosmehl H, Lauer I, Nadrowitz R, Wedel T and Sieg P: A comparative study on the protection profile of lidocaine, amifostine, and pilocarpin on the parotid gland during radiotherapy. *Cancer Res* 65: 10486-10493, 2005.

- 27 Hakim SG, Schroder C, Geerling G, Lauer I, Wedel T, Kosmehl H, Driemel O, Jacobsen HC, Trenkle T, Hermes D and Sieg P: Early and late immunohistochemical and ultrastructural changes associated with functional impairment of the lachrymal gland following external beam radiation. *Int J Exp Pathol* 87: 65-71, 2006.
- 28 Beutel J, Schroder C, von Hof K, Rades D, Kosmehl H, Wedel T, Sieg P, Geerling G and Hakim SG: Pharmacological prevention of radiation-induced dry eye – an experimental study in a rabbit model. *Graefes Arch Clin Exp Ophthalmol* 245: 1347-1355, 2007.
- 29 Dreyer JO, Sakuma Y and Seifert G: Die Strahlen-Sialadenitis. Stadieneinteilung und Immunhistologie. *Pathologe* 10: 165-170, 1989.
- 30 Seifert G, Miehke A, Haubrich J and Chilla R: Speicheldrüsenkrankheiten. *In: Pathologie-Klinik-Therapie-Fazialischirurgie*. Stuttgart: Thieme-Verlag, 1984.
- 31 Bartel-Friedrich S, Lautenschläger C, Holzhausen HJ and Friedrich RE: Expression and distribution of cytokeratins and vimentin in rat larynx and trachea following irradiation. *Anticancer Res* 27: 2059-2070, 2007.
- 32 Chung CY, Zardi L and Erickson HP: Binding of tenascin-C to soluble fibronectin and matrix fibrils. *J Biol Chem* 270: 29012-29017, 1995.
- 33 Ramos DM, Chen B, Regezi J, Zardi L and Pytela R: Tenascin-C matrix assembly in oral squamous cell carcinoma. *Int J Cancer* 75: 680-687, 1998.

Received August 19, 2009

Revised March 10, 2010

Accepted March 16, 2010