Efficiency of Iloprost Treatment for Chemotherapy-associated Osteonecrosis after Childhood Cancer

MARCUS JÄGER*, CHRISTOPH ZILKENS*, BETTINA WESTHOFF, EVA MARIA JELINEK, GORDANA KOZINA and RÜDIGER KRAUSPE

Department of Orthopedic Surgery, Heinrich-Heine University of Düsseldorf, 40225 Düsseldorf, Germany

Abstract. *Background: The risk of developing avascular osteonecrosis (AVN) after chemotherapy is age related and, at up to 17% of all treated patients, relatively high. Patients and Methods: In a prospective study, 8 patients (4 male, 4 female, 14.3±4.9 years old) were treated for symptomatic chemotherapy-associated AVN with intravenous infusion of iloprost. Association Research Circulation Osseus (ARCO) stages I-IV in 37 bones (25 joints) were treated. Results: Follow-up was 20.8±17 months (range: 6-53 months). No serious adverse reactions due to the infusion with iloprost were recorded. Pain levels were lower and functional outcome measured as Harris Hip and Knee Society Scores improved by the latest follow up. Conclusion: Our current data confirm the findings of other investigators that healing of advanced stages of AVN is not possible, but that in early stages of AVN, pain relief and an improvement of joint function can be achieved by iloprost.*

The employment of modified chemotherapy protocols for children and adolescents with leukemia and lymphoma results in significantly improved survival rates (1). The reported incidence of avascular necrosis (AVN) and bone marrow edema (BME) after chemotherapy for these diseases varies considerately and ranges from 4% to 23% in retrospective reports enrolling symptomatic patients (1-4) to up to 38% in prospective magnetic resonance imaging (MRI) studies (5-7). The great majority of chemotherapy-associated AVN occurs within three years after initiation of the therapy (1, 2, 8-10).

Glucocorticosteroids (GCS) are an integral part of most chemotherapy protocols for leukemia and lymphoma but represent a known risk factor for the development of AVN. Pathogenesis of AVN after chemotherapy is multifactorial and complex and is reviewed comprehensively elsewhere (11, 12). It includes suppression of osteoblasts, apoptosis of osteocytes, intramedullary lipocyte proliferation and fat hypertrophy, adverse effects on nutrient arteries contributing to thrombosis and fat embolism and damage to endothelial and smooth muscle cells of the venous system promoting further vascular stasis and ischaemia. In addition, prothrombotic factors are increased in the blood (thrombin, cholesterin and others). According to Kenzora's theory of accumulative cell stress (13), GCS play a "necessary but not sufficient role" in transforming bone marrow into fat with the risk of microembolism and a negative effect on microcirculation, resulting in a compartment syndrome of the bone. Recent *in vitro* studies investigated the impact of GCS in the pathogenesis of AVN after chemotherapy including the enhanced GSC-induced differentiation of mesenchymal stem cells (MSC) into lipocytes at the expense of osteogenesis (14, 15). Additional adverse effects may be due to the dose of asparaginase or methotrexate (16) in chemotherapy protocols. The cytotoxic effect of the chemotherapeutic drug itself may also play a role in the development of AVN, as AVN can also occur after chemotherapy without the use of GCS (17). While the impact of the steroid administered (usually dexamethasone or prednisone) and of the cumulative doses of GCS remains controversial, other risk factors for the development of AVN after chemotherapy are age >15 years, Caucasian race, female gender and distinct pharmacogenetic parameters, such as the vitamin D receptor FokI start site CC genotype (1, 2, 8, 9, 18, 19).

The clinical picture of AVN after chemotherapy is highly variable and ranges from a virtual absence of symptoms to painful immobilization of the patient (10). It is commonly multifocal and bilateral and the weight bearing regions of hips and knee joints are most frequently affected and symptomatic (20).

*Both authors contributed equally to this work.

Correspondence to: Marcus Jäger, MD, Ph.D., Department of Orthopedic Surgery, Heinrich-Heine University Medical School, D-40225 Düsseldorf, Germany. Tel: +49 02118118580, Fax: +49 021116693, e-mail: Jaeger@med.uni-duesseldorf.de

Key Words: Osteonecrosis, iloprost, chemotherapy, prostaglandin.

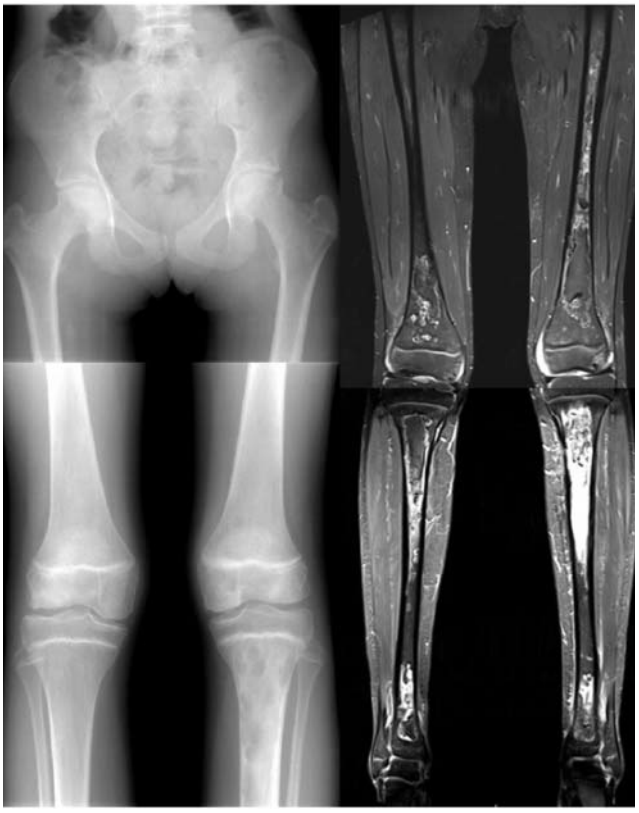

Figure 1. *Magnetic resonance image (MRI) of a 7-year-old girl with multifocal and chemotherapy-associated AVN of both legs.*

The treatment of patients with chemotherapy-associated AVN is challenging for both the hematologist and the orthopedic surgeon. Evidence-based, standardized therapeutic concepts or treatment guidelines are not available for this group of young patients and several operative and non-operative treatment options are subject to controversial discussion. The vasoactive, stable prostacyclin analog iloprost is approved for therapy of critical ischemia due to peripheral arteriosclerotic obliterative disease and diabetic angiopathy and as an inhalative for patients with pulmonary arterial hypertension (21). Other indications for iloprost application are systemic sclerosis, bone pain due to sickle cell crisis, Morbus Raynaud and systemic lupus erythematosus (21-24). The use of iloprost for the treatment of painful BME and AVN represents an off-label use and due to promising results of other groups (25-29) and to our own positive experience (30), we started a prospective study on the curative potential and analgesic efficiency of iloprost in 2004 (31). In this case series, we present our first data of the efficiency of iloprost for chemotherapy-associated AVN and BME in pediatric and young adult patients (Figure 1).

Table I. *Iloprost infusion scheme.*

Body weight (kg)	Day 1 [ml/h] (0.5 ng/kg/min)	Day 2 [ml/h] (0.75 ng/kg/min)	Days 3-5 [ml/h] (1.0 ng/kg/min)
30	1.1	1.7	2.25
40	1.5	2.25	3.0
50	1.9	2.85	3.75
60	2.2	3.4	4.5
70	2.6	4.0	5.3
80	3.0	4.5	6.0
90	3.4	5.1	6.8

Patients and Methods

In a prospective study consisting of 130 patients with painful BME or AVN, 8 patients with symptomatic BME or AVN due to chemotherapy for acute lymphoblastic leukemia (ALL: 7 patients) and Hodgkin lymphoma (1 patient) were treated with iloprost between September 2005 and February 2008. All patients received chemotherapy according to the treatment protocol of the German Society of Paediatric Oncology and Haematology (GPOH), described in detail elsewhere (32, 33). Four females and 4 males with an average age of 14.3 years ± 4.9 (range: 8.3-23.7 years), average body weight of 54 kg ± 21 (range: 31-84 kg), and an average height of 160 cm ± 17 (range: 130-183 cm) were treated. The time range between the beginning of chemotherapy and onset of symptoms was 16.9±12.5 months (range: 5-39 months) and between the beginning of bone-related pain and diagnosis of BME or AVN was 1.0±1.5 months (range: 0.5-5.1 months). Inclusion criteria were pediatric and young adult patients with painful BME or AVN after chemotherapy. Exclusion criteria were acute and chronic infections, hypertension with systolic values >160 mmHg, ischemic heart attack or cerebral ischemia. The study protocol was approved by the local Ethics Committee (trial No: 2355). Written informed consent of the patients and parents was obtained according to the Declaration of Helsinki in its present version.

Iloprost (Ilomedin®, BAYER Healthcare, formally Schering AG, Germany) was dissolved in 0.9% saline solution and applied intravenously over a period of 6 hours per day in a weight-related scheme for a total of 5 days (Table I). Patients were hospitalized and monitored closely for possible adverse effects. Side-effects were categorized as severe (hypotension, arrhythmia, bleeding, thromboembolism, acute respiratory distress syndrome, pulmonary edema, allergic reactions with systemic clinical signs, shock) and minor (flush, erythema, headache, nausea, phlebitis). Based on medical history and clinical examination, the Harris Hip Score (HHS), and the Knee Society Score (KSS) served for functional evaluation during follow-up. For the assessment of pain level, a visual analogue scale (VAS) was used ranging from 0-10 points with 0 points representing freedom of pain and 10 points representing worst imaginable pain. Plain radiographs and magnetic resonance imaging (MRI) scans (T1-/T2-/STIR-weighted) were performed for radiographic analysis by a blinded independent radiologist (parameters: ARCO stages and extent of BME, progression, persistence, regression). Statistical analysis was performed by using SPSS 15.0 (SPSS Inc, Chicago, IL, USA) software package. Student's *t*-test for independent statistical groups was used

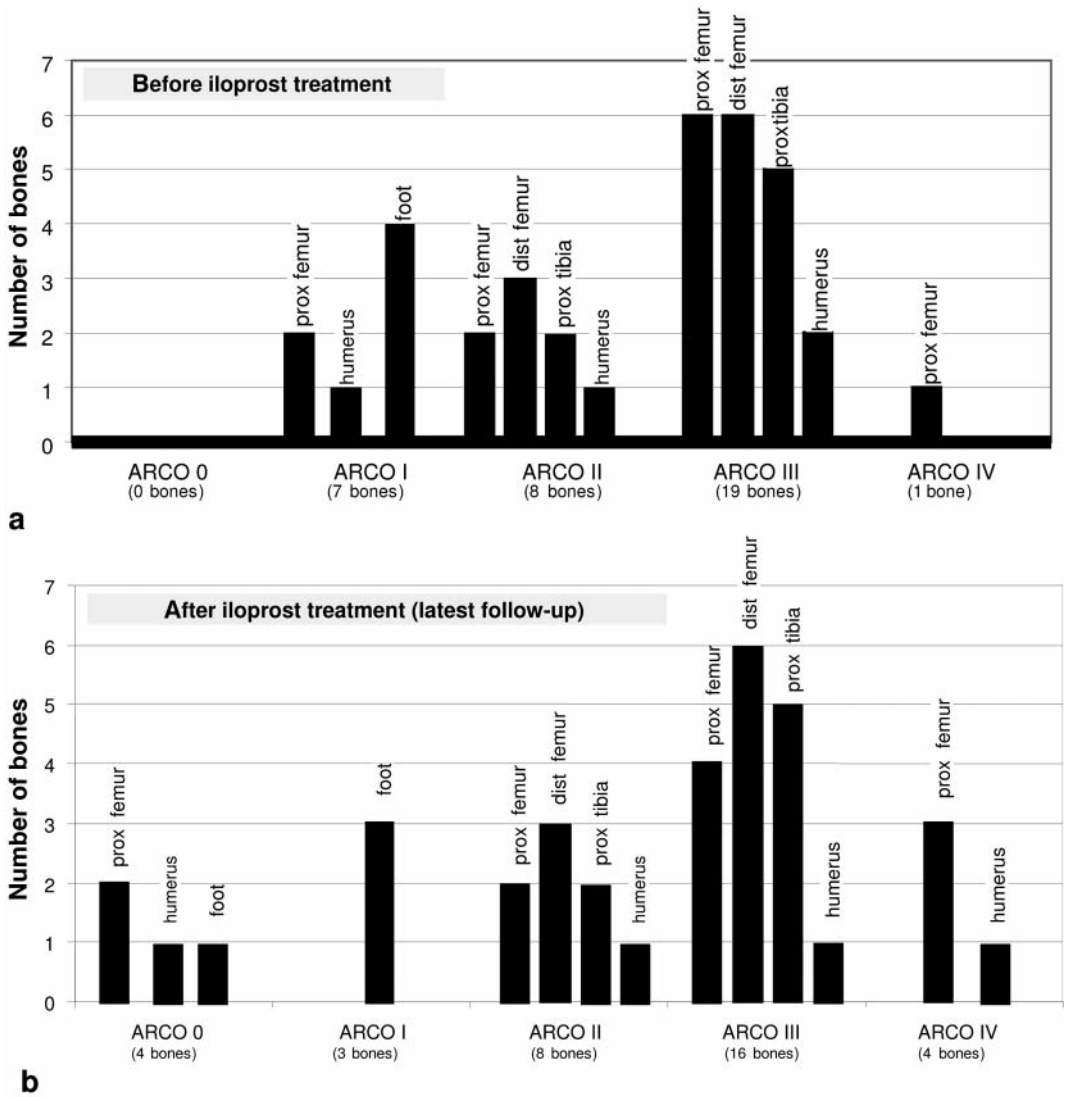

Figure 2. *Regional distribution of AVN / BME and corresponding ARCO stages before (a) and after (b) iloprost therapy. dist, Distal; prox, proximal.*

with $p<0.001$ indicating high statistical significance. Due to the low case number, statistical analysis was less meaningful and is therefore not included.

Results

Thirty-seven bones (25 joints) were affected by BME/AVN before treatment. The most recent follow-up was 20.8±17 months (range: 6-53 months). Figure 2a and b and Table II shows the regional distribution and ARCO stages in the 8 patients before and after treatment. Table III presents the patient data: on average, 4.6±3.5 bones (range: 1-11 bones) in 3.1±2 joints (range: 1-6 joints) were affected per patient. In 7 patients, hips and/or knees were affected and 6 patients had a bilateral distribution of AVN. Three patients were subject to core decompression 9±1.7 days (range: 8-11 days) prior to iloprost therapy. Two patients underwent further surgery (core decompression in patient no. 1, and cancellous bone transplantation in patient no. 8 at 10 and 30 months after iloprost treatment, respectively).

No severe side-effects were observed during intravenous application of iloprost. Less severe side-effects such as headache, nausea, vomitus or phlebitis were recorded in 5 patients and resulted in a dose reduction of iloprost only in patient 1 at days 2 and 5. Pain levels were reduced and functional scores improved in the course of treatment as shown in Figures 3-5. The VAS score of 5±2 (range: 3-7) was reduced to 2±2 (range: 0-5) at 3 months and persisted at

Table II. *ARCO stages before and after treatment.*

	ARCO 0	ARCO I	ARCO II	ARCO III	ARCO IV
			Proximal femur		
Before treatment	0	2	2	6	1
Last follow-up	2	0	2	4	3
			Distal femur		
Before treatment	0	0	3	6	0
Last follow-up	0	0	3	6	0
			Proximal tibia		
Before treatment	0	0	2	5	0
Last follow-up	0	0	2	5	0
			Humerus		
Before treatment	0	1	1	2	0
Last follow-up	1	0	1	1	1
			Foot		
Before treatment	0	4	0	0	0
Last follow-up	1	3	0	0	0

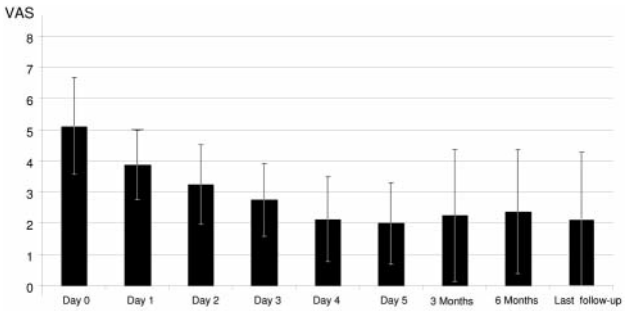

Figure 3. *Average pain level in the course of treatment.*

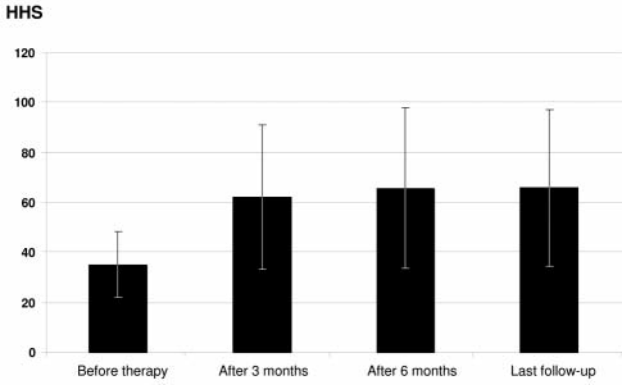

Figure 4. *Harris Hip Score in the course of treatment.*

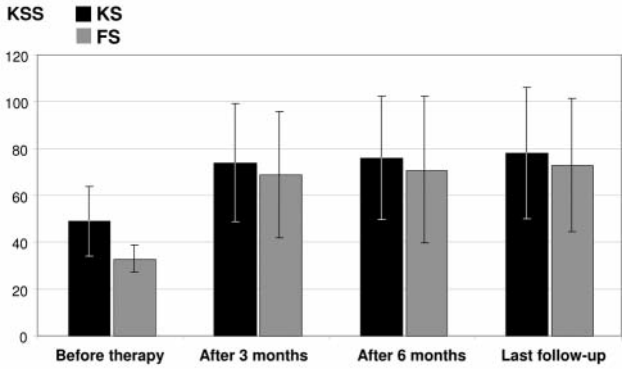

Figure 5. *Knee Society Score (KS, knee score; FS, functional score) in the course of treatment.*

this level also at 6 months and the most recent follow-up. The Harris Hip Score improved from 35±13 (range: 24-60) before treatment to 62±29 (range: 36-92) after 3 months, to 66±32 (range: 36-98) after 6 months and to 66±31 (range: 36-98) at the most recent follow-up. The Knee Society Score *knee score* showed an improvement from 49±15 (range: 25-65) before treatment to 74±25 (range: 35-100) after 3 months, to 76±26 (range: 33-100) after 6 months and to 78±28 (range: 35-100) at the latest follow-up. The Knee Society *functional score* showed an improvement from 33±6 (range: 25-45) before treatment to 69±27 (range: 40-100) after 3 months, to 71±31 (range: 33-100) after 6 months and to 73±29 (range: 40-100) at the most recent follow-up.

On MRI scans, a reduction of BME was documented in 3 patients (both proximal femora, patient 3; humerus, patient 5; calcaneus, patient 8) (Table III, Figure 6). In 3 cases, ARCO III progressed into ARCO IV. For the remaining patients, AVN was no longer progressive and a steady state was noted.

Discussion

The variable nature of osteonecrosis and BME after chemotherapy and the variable course of the underlying disease impedes decision making for a certain therapeutic strategy. In two studies from Finland, more than one third of children with ALL showed radiological evidence of AVN, with the majority of patients being asymptomatic, some showing regression and a few even complete *restitutio ad integrum* (5, 6). Large co-operative studies have highlighted that fact that about 24-42% of patients with symptomatic AVN have undergone some form of orthopaedic surgery (2, 18).

Table III. *The table summarizes relevant patient data.*

Patient no.	Gender	Age (years)	Body height (cm)	Weight (kg)	Diagnosis	Affected joints	Affected bones	Time (months) from… …chemotherapy to symptoms	… symptoms to diagnosis of AVN	Follow-up (months)	Adverse effects during infusion	Intervention before iloprost application	Intervention after iloprost application	Subjedive overal valuation
1	M	18.1	170	50.3	ALL	Both knees	4	5.0	2.0	31.0	Nausea, headache, phlebitis	-	Core decompression	Negative
2	F	16.0	171	84.0	ALL	Both hips	2	39.3	1.0	13.2	No complaints	Core decompression	-	Positive
3	F	10.0	143	31.0	ALL	Both hips/ knees and shoulders	8	11.1	1.0	6.1	No complaints	-	-	Positive
4	F	13.7	167	42.0	ALL	Both hips/ knees	6	16.2	1.0	7.7	Mild headache	Core decompression	-	Neutral
5	M	12.4	152	65.0	ALL	1 ellbow	1	30.4	0.5	12.7	Nausea	-	-	Positive
6	F	8.3	130	31.0	ALL	1 hip	1	7.4	0.7	8.1	No complaints	-	-	Positive
7	M	23.7	183	80.0	Hodgkin	Both hips, 1 knee	4	14.0	2.0	52.7	Mild headache	Core decompression	-	Positive
8	M	11.9	164	42.0	ALL	1 Hip/ shoulder, boths knees	11	5.0	5.1	35.9	Nausea, headache, vomiting	-	Cancellous bone grafting	Neutral

ALL, Acute lymphoblastic leukemia; M, male; F, female.

There is no doubt that for patients with extensive or painful AVN or BME, some form of intervention is necessary in addition to discontinuation of physical activity and weight-bearing (34). In contrast to the advice, however, which for asymptomatic patients with small AVN lesions or BME observing and monitoring is appropriate, we suggest that early intervention and therapy in still reversible early ARCO stages.

Different surgical strategies for joint preserving procedures were reported (35). For several reasons, in children and young adults there is a need to avoid or as far as possible delay joint replacement, especially in patients with remaining significant growth (36). In selected cases and with critical indication, hemi-arthro-resurfacing procedures might be beneficial for young patients (37). Arthrodeses are not indicated in patients with more than one joint involved (38). Osteotomies might be beneficial for circumscribed lesions of the femoral head, if the osteonecrotic defect can be moved out of the weight bearing area. Because of the uncertain surgical outcome and increased co-morbidity with the risk of further compromising bone nutrition, the indication for osteotomies is rare (38). Core decompression in early stages of AVN is meant to relieve intra-osseous hypertension and venous congestion, improve microcirculation and allow remodeling of the bone (35). After core decompression, grafting with autologous bone marrow has been described with good medium-term outcome (39). Based on the evidence that MSCs are reduced in number and function in areas of AVN, several groups have administered autologous bone-marrow cells with moderate medium-term outcome (39-43). The use of vascularized fibular bone graft is technically demanding and long-term results are not convincing (44). Biological resurfacing of the joint with cartilage-bone transplantation is suitable for small defects at the knee joint. Non-surgical treatment strategies for AVN or BME may include hyperbaric oxygen therapy (45), external electrical stimulation (46), capacitance coupling (47), or the administration of heparin or other anticoagulants (48). The use of alendronate – a third generation bisphosphonate – seems to delay bone collapse by osteoclast inhibition (49-51).

The pharmacokinetic effects of iloprost are multiple: iloprost leads to vasodilatation but also improves the microcirculation by affecting the rheological properties of the terminal vascular bed, reducing capillary permeability, inhibiting platelet aggregation and diminishing the concentration of oxygen free radicals and leukotrienes (52). Aigner *et al*. successfully treated patients with BME of the forefoot and the acetabulum in 2001 and 2002 with iloprost (26, 28) and was the first to

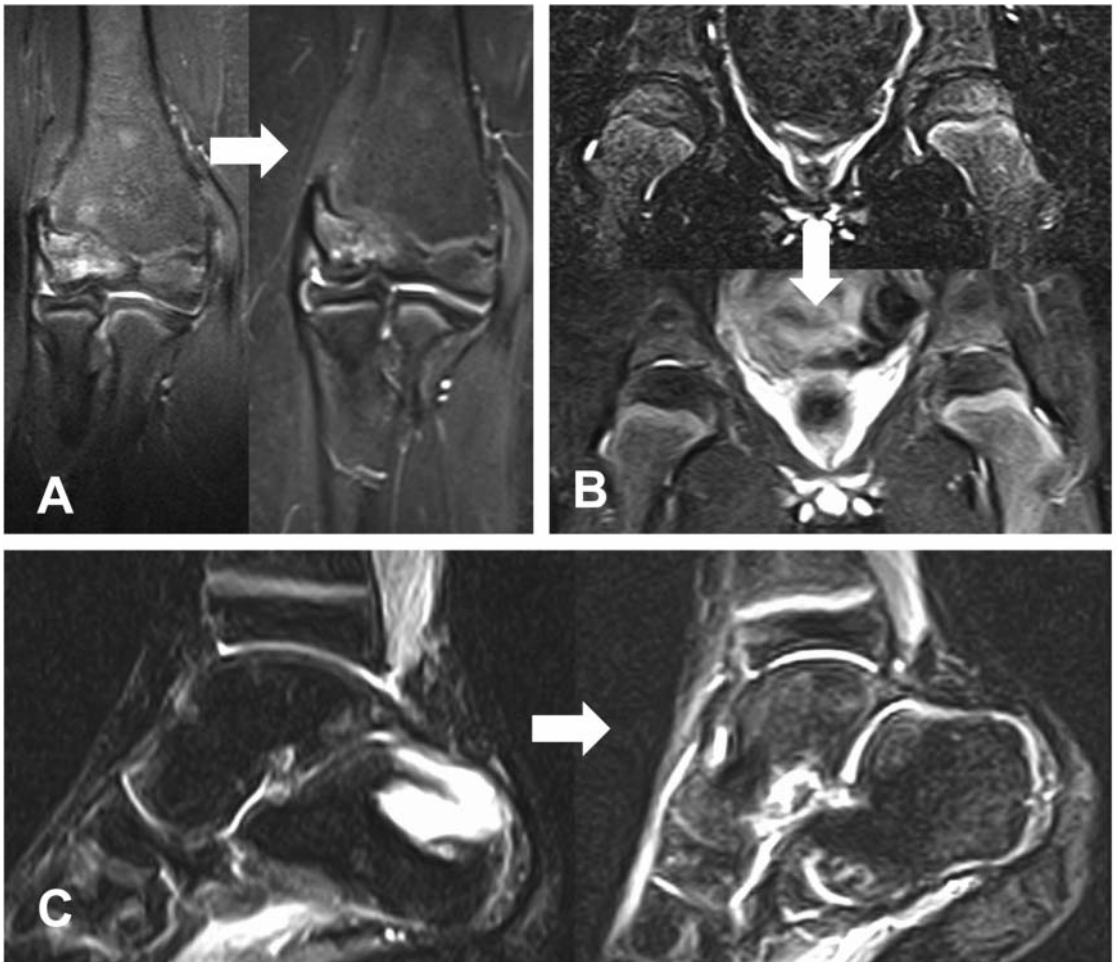

Figure 6. *Examples of regression of bone marrow edema after iloprost treatment: A: elbow (patient 5); B: both proximal femora (patient 3); C: talus and calcaneus (patient 8).*

demonstrate a clinical benefit, especially in early stages of the disease. These findings were reproduced by further studies (29, 31, 53, 54). Our data show that the pain level could be reduced and functional scores improved during-follow up after iloprost-application in chemotherapy-associatiated AVN. When asked at the most recent follow-up about their overall subjective rating of treatment with iloprost including the experienced side-effects and benefit, 5 patients had a positive, one patient a neutral and 2 patients a negative attitude toward treatment with iloprost. According to current data, healing of advanced stages of AVN is not possible. However, the results of this case series confirm our previous findings in adults (31) that iloprost can also contribute to the relief of pain and improvement of joint function in children and young adults in early precollapse stages of AVN (ARCO I and II). Larger long-term studies will show whether or not iloprost can halt or reverse chemotherapy-associated AVN in pediatric and young adult patients, at least in early stages.

References

1 Strauss AJ, Su JT, Dalton VM, Gelber RD, Sallan SE and Silverman LB: Bony morbidity in children treated for acute lymphoblastic leukemia. J Clin Oncol *19(12)*: 3066-3072, 2001.

2 Mattano LA Jr, Sather HN, Trigg ME and Nachman JB: Osteonecrosis as a complication of treating acute lymphoblastic leukemia in children: a report from the Children's Cancer Group. J Clin Oncol *18(18)*: 3262-3272, 2000.

3 Raab P, Kuhl J and Krauspe R: Multifocal osteonecrosis in children and adolescents after polychemotherapy. Z Orthop Ihre Grenzgeb *135(5)*: 444-450, 1997 (in German).

4 Wei SY, Esmail AN, Bunin N and Dormans JP: Avascular necrosis in children with acute lymphoblastic leukemia. J Pediatr Orthop *20(3)*: 331-335, 2000.

5 Ojala AE, Lanning FP, Paakko E and Lanning BM: Osteonecrosis in children treated for acute lymphoblastic leukemia: a magnetic resonance imaging study after treatment. Med Pediatr Oncol *29(4)*: 260-265, 1997.

6 Ojala AE, Paakko E, Lanning FP and Lanning M: Osteonecrosis during the treatment of childhood acute lymphoblastic leukemia: a prospective MRI study. Med Pediatr Oncol *32(1)*: 11-17, 1999.

7 Ojala AE, Paakko E, Lanning FP, Harila-Saari AH and Lanning BM: Bone marrow changes on MRI in children with acute lymphoblastic leukaemia 5 years after treatment. Clin Radiol *53(2)*: 131-136, 1998.

8 Arico M, Boccalatte MF, Silvestri D, Barisone E, Messina C, Chiesa R, Santoro N, Tamaro P, Lippi A, Gallisai D, Basso G and De Rossi G: Osteonecrosis: An emerging complication of intensive chemotherapy for childhood acute lymphoblastic leukemia. Haematologica *88(7)*: 747-753, 2003.

9 Hogler W, Wehl G, van Staa T, Meister B, Klein-Franke A and Kropshofer G: Incidence of skeletal complications during treatment of childhood acute lymphoblastic leukemia: comparison of fracture risk with the General Practice Research Database. Pediatr Blood Cancer *48(1)*: 21-27, 2007.

10 Jäger M, Balzer S, Wessalowski R, Schaper J, Gobel U, Li X and Krauspe R: Hyperthermia associated osteonecrosis in young patients with pelvic malignancies. Anticancer Agents Med Chem *8(5)*: 571-575, 2008.

11 Jäger M and Krauspe R: Osteonekrosen – Pathogenese, Diagnostik, Therapie, Verlauf. London, International Medical Publishers, Unimed Verlag, 2007.

12 Cruess RL: Steroid-induced osteonecrosis: a review. Can J Surg *24(6)*: 567-571, 1981.

13 Kenzora JE: Treatment of idiopathic osteonecrosis: the current philosophy and rationale. Orthop Clin North Am *16(4)*: 717-725, 1985.

14 Motomura G, Yamamoto T, Miyanishi K, Yamashita A, Sueishi K and Iwamoto Y: Bone marrow fat-cell enlargement in early steroid-induced osteonecrosis – a histomorphometric study of autopsy cases. Pathol Res Pract *200(11-12)*: 807-811, 2005.

15 Lee JS, Roh HL, Kim CH, Jung JS and Suh KT: Alterations in the differentiation ability of mesenchymal stem cells in patients with nontraumatic osteonecrosis of the femoral head: comparative analysis according to the risk factor. J Orthop Res *24(4)*: 604-609, 2006.

16 Hanada T, Horigome Y, Inudoh M and Takita H: Osteonecrosis of vertebrae in a child with acute lymphocytic leukaemia during L-asparaginase therapy. Eur J Pediatr *149(3)*: 162-163, 1989.

17 Murphy RG and Greenberg ML: Osteonecrosis in pediatric patients with acute lymphoblastic leukemia. Cancer *65(8)*: 1717-1721, 1990.

18 Burger B, Beier R, Zimmermann M, Beck JD, Reiter A and Schrappe M: Osteonecrosis: a treatment related toxicity in childhood acute lymphoblastic leukemia (ALL) – experiences from trial ALL-BFM 95. Pediatr Blood Cancer *44(3)*: 220-225, 2005.

19 Relling MV, Yang W, Das S, Cook EH, Rosner GL, Neel M, Howard S, Ribeiro R, Sandlund JT, Pui CH and Kaste SC: Pharmacogenetic risk factors for osteonecrosis of the hip among children with leukemia. J Clin Oncol *22(19)*: 3930-3936, 2004.

20 Group CO: Symptomatic multifocal osteonecrosis. A multicenter study. Clin Orthop Relat Res *369*: 312-326, 1999.

21 Hsu HH and Rubin LJ: Iloprost inhalation solution for the treatment of pulmonary arterial hypertension. Expert Opin Pharmacother *6(11)*: 1921-1930, 2005.

22 Disch AC, Matziolis G, Reinke P and Perka C: Intravenous Iloprost treatment for severe bone pain caused by sickle cell crisis. Thromb Haemost *91(5)*: 1047-1049, 2004.

23 Marasini B, Massarotti M, Bottasso B, Coppola R, Papa ND, Maglione W, Comina DP and Maioli C: Comparison between iloprost and alprostadil in the treatment of Raynaud's phenomenon. Scand J Rheumatol *33(4)*: 253-256, 2004.

24 Foti C, Cassano N, Conserva A, Coviello C, De Meo M and Vena GA: Diffuse cutaneous systemic sclerosis treated with intravenous iloprost. Clin Exp Dermatol *29(3)*: 321-323, 2004.

25 Aigner N, Meizer R, Stolz G, Petje G, Krasny C, Landsiedl F and Steinboeck G: Iloprost for the treatment of bone marrow edema in the hindfoot. Foot Ankle Clin *8(4)*: 683-693, 2003.

26 Aigner N, Petje G, Schneider W, Krasny C, Grill F and Landsiedl F: Juvenile bone marrow oedema of the acetabulum treated by iloprost. J Bone Joint Surg Br *84(7)*: 1050-1052, 2002.

27 Aigner N, Petje G, Schneider W, Meizer R, Wlk M, Kotsaris S, Knahr K and Landsiedl F: Bone marrow edema syndrome of the femoral head: treatment with the prostacyclin analogue iloprost *vs*. core decompression: an MRI-controlled study. Wien Klin Wochenschr *117(4)*: 130-135, 2005.

28 Aigner N, Petje G, Steinboeck G, Schneider W, Krasny C and Landsiedl F: Treatment of bone-marrow oedema of the talus with the prostacyclin analogue iloprost. An MRI-controlled investigation of a new method. J Bone Joint Surg Br *83(6)*: 855-858, 2001.

29 Disch AC, Matziolis G and Perka C: The management of necrosis-associated and idiopathic bone-marrow oedema of the proximal femur by intravenous iloprost. J Bone Joint Surg Br *87(4)*: 560-564, 2005.

30 Jäger M, Werner A, Lentrodt S, Modder U and Krauspe R: Pain management in non-juvenile, aseptic osteonecrosis. Schmerz *18(6)*: 481-491, 2004 (in German).

31 Jäger M, Tillmann FP, Thornhill TS, Mahmoudi M, Blondin D, Hetzel GR, Grabensee B, Zilkens C and Krauspe R: Rationale for PGI2 in bone regeneration: from theory to application. Arthritis Res Therapy *10(5)*: R120, 2008.

32 Harms DO and Janka-Schaub GE: Co-operative study group for childhood acute lymphoblastic leukemia (COALL): long-term follow-up of trials 82, 85, 89 and 92. Leukemia *14(12)*: 2234-2239, 2000.

33 Reiter A, Schrappe M, Tiemann M, Ludwig WD, Yakisan E, Zimmermann M, Mann G, Chott A, Ebell W, Klingebiel T, Graf N, Kremens B, Muller-Weihrich S, Pluss HJ, Zintl F, Henze G and Riehm H: Improved treatment results in childhood B-cell neoplasms with tailored intensification of therapy: A report of the Berlin-Frankfurt-Munster Group Trial NHL-BFM 90. Blood *94(10)*: 3294-3306, 1999.

34 Hungerford DS and Jones LC: Asymptomatic osteonecrosis: should it be treated? Clin Orthop Relat Res *429*: 124-130, 2004.

35 Werner A, Jager M, Schmitz H and Krauspe R: Joint preserving surgery for osteonecrosis and osteochondral defects after chemotherapy in childhood. Klin Padiatr *215(6)*: 332-337, 2003.

36 Jäger M, Begg MJ, Ready J, Bittersohl B, Millis M, Krauspe R and Thornhill TS: Primary total hip replacement in childhood, adolescence and young patients: quality and outcome of clinical studies. Technol Health Care *16(3)*: 195-214, 2008.

37 Jäger M, Begg MJ and Krauspe R: Partial hemi-resurfacing of the hip joint – a new approach to treat local osteochondral defects? Biomed Tech (Berl) *51(5-6)*: 371-376, 2006.

38 Westhoff B, Jäger M and Krauspe R: Osteonecrosis after chemotherapy in children. Orthopäde *37(1)*: 56-62, 2008 (in German).
39 Hernigou P and Beaujean F: Treatment of osteonecrosis with autologous bone marrow grafting. Clin Orthop Relat Res *405*: 14-23, 2002.
40 Hernigou P, Beaujean F and Lambotte JC: Decrease in the mesenchymal stem-cell pool in the proximal femur in corticosteroid-induced osteonecrosis. J Bone Joint Surg Br *81(2)*: 349-355, 1999.
41 Gangji V, Toungouz M and Hauzeur JP: Stem cell therapy for osteonecrosis of the femoral head. Expert Opin Biol Ther *5(4)*: 437-442, 2005.
42 Gangji V and Hauzeur JP: Treatment of osteonecrosis of the femoral head with implantation of autologous bone marrow cells. Surgical technique. J Bone Joint Surg Am *87 Suppl 1(Pt 1)*: 106-112, 2005.
43 Yan ZQ, Chen YS, Li WJ, Yang Y, Huo JZ, Chen ZR, Shi JH and Ge JB: Treatment of osteonecrosis of the femoral head by percutaneous decompression and autologous bone marrow mononuclear cell infusion. Chin J Traumatol *9(1)*: 3-7, 2006.
44 Yen CY, Tu YK, Ma CH, Yu SW, Kao FC and Lee MS: Osteonecrosis of the femoral head: comparison of clinical results for vascularized iliac and fibula bone grafting. J Reconstr Microsurg *22(1)*: 21-24, 2006.
45 Bernbeck B, Christaras A, Krauth K, Lentrodt S, Strelow H, Schaper J, Janssen G, Modder U and Gobel U: Bone marrow oedema and aseptic osteonecrosis in children and adolescents with acute lymphoblastic leukaemia or non-Hodgkin-lymphoma treated with hyperbaric-oxygen-therapy (HBO): an approach to cure? - BME/AON and hyperbaric oxygen therapy as a treatment modality. Klin Padiatr *216(6)*: 370-378, 2004.
46 Trancik T, Lunceford E and Strum D: The effect of electrical stimulation on osteonecrosis of the femoral head. Clin Orthop Relat Res *256*: 120-124, 1990.
47 Steinberg ME: Osteonecrosis of the hip: summary and conclusions. Semin Arthroplasty 2(3): 241-249, 1991.
48 Glueck CJ, Freiberg RA, Sieve L and Wang P: Enoxaparin prevents progression of stages I and II osteonecrosis of the hip. Clin Orthop Relat Res *435*: 164-170, 2005.
49 Nishii T, Sugano N, Miki H, Hashimoto J and Yoshikawa H: Does alendronate prevent collapse in osteonecrosis of the femoral head? Clin Orthop Relat Res *443*: 273-279, 2006.
50 Lai KA, Shen WJ, Yang CY, Shao CJ, Hsu JT and Lin RM: The use of alendronate to prevent early collapse of the femoral head in patients with nontraumatic osteonecrosis. A randomized clinical study. J Bone Joint Surg Am *87(10)*: 2155-2159, 2005.
51 Atkinson SA, Halton JM, Bradley C, Wu B and Barr RD: Bone and mineral abnormalities in childhood acute lymphoblastic leukemia: influence of disease, drugs and nutrition. Int J Cancer Suppl *11*: 35-39, 1998.
52 Grant SM and Goa KL: Iloprost. A review of its pharmacodynamic and pharmacokinetic properties, and therapeutic potential in peripheral vascular disease, myocardial ischaemia and extracorporeal circulation procedures. Drugs *43(6)*: 889-924, 1992.
53 Meizer R, Radda C, Stolz G, Kotsaris S, Petje G, Krasny C, Wlk M, Mayerhofer M, Landsiedl F and Aigner N: MRI-controlled analysis of 104 patients with painful bone marrow edema in different joint localizations treated with the prostacyclin analogue iloprost. Wien Klin Wochenschr *117(7-8)*: 278-286, 2005.
54 Tillmann FP, Jager M, Blondin D, Schooldermann D, Voiculescu A, Sucker C, Grabensee B, Krauspe R and Hetzel GR: Intravenous iloprost: a new therapeutic option for patients with post-transplant distal limb syndrome (PTDLS). Am J Transplant *7(3)*: 667-671, 2007.

Received January 12, 2009
Revised March 5, 2009
Accepted April 9, 2009